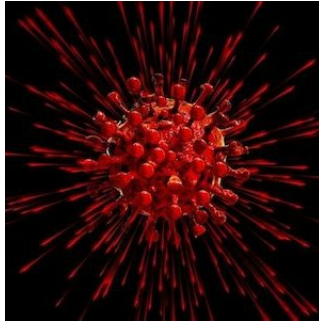


Ultrasound Has Role in COVID-19 Detection



Recent research mostly from China, where the new coronavirus disease 2019 (COVID-19) outbreak originated, has cited the usefulness of chest CT in early disease diagnosis. CT protocols are now used for assessing pulmonary damage in COVID-19 patients.

You might also like: [COVID-19 Will Revolutionise Imaging Practices](#)

Since CT scanning is often not available in emergency departments, a group of emergency physicians in Italy – one of the many countries severely affected by the pandemic – says ultrasound can be used as an alternative diagnostic tool. Lung ultrasound is a surface imaging technique strongly recommended for assessment of acute respiratory failure, according to the Italian physicians affiliated with the Department of Emergency Medicine at [Ospedale Guglielmo da Saliceto in Piacenza, Italy](#). They also noted that lung US is commonly used in the ED to diagnose pneumonia at patients' bedsides.

From an analysis of 12 patients with flu-like symptoms and COVID-19 pneumonia, Erika Poggiali, MD, and colleagues observed “strong correlation” between ultrasound and CT findings.

The correlation between CT and ultrasound included bilateral lung involvement with ground-glass opacity. In addition, a “crazy-paving pattern” was noted in 5 of 12 patients, while organising pneumonia was detected in four patients using CT and later confirmed with lung ultrasound.

According to Dr Poggiali's team, all 12 patients had a diffuse B-pattern with spared areas and none had severe respiratory distress. Only three patients had posterior subpleural consolidations.

“We are aware that our data are preliminary and further studies are necessary to confirm the role of lung US in the diagnosis and [management of COVID-19 pneumonia](#), but we strongly recommend the use of bedside US for the early diagnosis of COVID-19 pneumonia in all the patients who presented to the emergency department with flu-like symptoms in [the] novel COVID-19 era,” wrote Dr Poggiali and colleagues.

Meanwhile, an advisory issued by the American College of Radiology states that CT should be used sparingly in COVID-19 patients. Radiologists should reserve the modality for hospitalised, symptomatic patients with specific clinical indications for CT, ACR pointed out.

Source: [Radiology Business](#)

Image credit: Pixabay

Reference Poggiali E et al. (2020) Letter to the Editor: Can Lung US Help Critical Care Clinicians in the Early Diagnosis of Novel Coronavirus (COVID-19) Pneumonia?. Radiology; Published Online 13 March. <https://doi.org/10.1148/radiol.2020200847>

Published on : Mon, 30 Mar 2020

© For personal and private use only. Reproduction must be permitted by the copyright holder. Email to copyright@mindbyte.eu.

