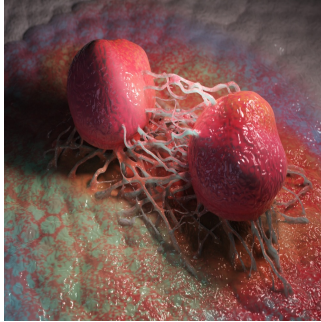


---

## Triple-Tracer PET Imaging in Metastatic Castration-Resistant Prostate Cancer



---

Metastatic castration-resistant prostate cancer (mCRPC) represents a highly challenging stage of prostate cancer, often characterised by heterogeneous tumour behaviour across different metastases. This complexity, referred to as intrapatient intermetastatic heterogeneity (IIH), can significantly affect treatment outcomes. Recent advances in molecular imaging, mainly through PET (Positron Emission Tomography) scans, offer promising tools for non-invasive characterisation of this heterogeneity. The 3TMPO cohort study investigated the prevalence of IIH and assessed eligibility for radiopharmaceutical therapy (RPT) using a unique triple-tracer PET imaging strategy. By employing three distinct tracers —18F-FDG, 68Ga-PSMA, and 68Ga-DOTATATE—, the study provides a comprehensive view of IIH in mCRPC patients and its impact on survival outcomes.

### Intrapatient Intermetastatic Heterogeneity in mCRPC

The phenomenon of IIH describes the presence of biologically diverse cancer cell clones within a single patient, where different metastases respond variably to treatment. The 3TMPO study found that a significant proportion (82.7%) of the mCRPC patients exhibited IIH, as revealed by dual-tracer PET scans with 18F-FDG and 68Ga-PSMA. This heterogeneity is a result of cancer's ability to undergo phenotypic plasticity, changing its characteristics in response to successive therapies. The presence of diverse lesion phenotypes within the same patient complicates treatment selection, making it essential to identify which metastases are responsive to specific therapies, particularly RPT.

In the study, 45.9% of patients had at least one 18F-FDG-positive and 68Ga-PSMA-negative lesion, indicating a significant portion of their disease was not amenable to PSMA-targeted therapies. This subset of patients would require alternative treatment strategies, as 18F-FDG-positive/68Ga-PSMA-negative lesions are typically associated with more aggressive and treatment-resistant forms of prostate cancer. Moreover, the prevalence of 68Ga-DOTATATE-positive lesions, though lower at 16.2%, further highlights the heterogeneity of the disease, with some patients developing neuroendocrine differentiation (NED), a more aggressive cancer subtype.

### Impact of Imaging Phenotypes on Treatment and Survival

The triple-tracer PET approach used in the 3TMPO study allows for a detailed examination of different lesion phenotypes and their correlation with treatment outcomes. By combining 18F-FDG, 68Ga-PSMA, and 68Ga-DOTATATE scans, the study identified 12 different phenotypic combinations across the patient cohort. These combinations reflect the diverse biological behaviour of metastases, underscoring the complexity of managing mCRPC.

Eligibility for PSMA RPT, which relies on positive uptake of the 68Ga-PSMA tracer, was found in 53.1% of patients. However, none of the patients were deemed eligible for DOTATATE RPT despite the presence of NED in some cases. This finding suggests that while PSMA-targeted therapies remain a viable option for many mCRPC patients, those with DOTATATE-positive lesions may require different therapeutic approaches due to the aggressive nature of NED.

Moreover, the study demonstrated a significant relationship between specific imaging phenotypes and overall survival (OS). Patients with IIH had a shorter median OS (9.5 months) than those without IIH, indicating that heterogeneity within metastases is a poor prognostic marker. Notably, patients with at least one 18F-FDG-positive/68Ga-PSMA-negative lesion had a median OS of just 5.6 months, emphasising the aggressive nature of these lesions. Similarly, the presence of a 68Ga-DOTATATE-positive lesion was associated with an inferior prognosis, with a median OS of only three months. These results highlight the need for personalised treatment strategies based on detailed imaging phenotypes to improve survival outcomes in mCRPC patients.

### The Role of Triple-Tracer PET Imaging in Precision Medicine

The 3TMPO study showcases the potential of triple-tracer PET imaging as a powerful tool for precision medicine in mCRPC. By providing a comprehensive assessment of the entire metastatic burden, this imaging strategy allows for better-informed clinical decisions, such as identifying the most appropriate sites for biopsy or selecting candidates for RPT. Identifying multiple phenotypes within a single patient also opens the door to combination therapies that target different pathways within the cancer's biology, potentially improving outcomes compared to monotherapy.

Combining 18F-FDG, 68Ga-PSMA, and 68Ga-DOTATATE PET scans can also help clinicians tailor their approach to individual patients, especially when standard therapies are ineffective. For instance, patients with predominantly 18F-FDG-positive/68Ga-PSMA-negative lesions may benefit from treatments targeting more aggressive tumour biology. In contrast, those with 68Ga-DOTATATE-positive lesions might be considered for experimental therapies or palliative care due to the poor prognosis associated with NED.

However, the study also highlights some limitations of current PET imaging techniques. While clinically useful, the dichotomisation of lesions as positive or negative for specific tracers does not fully capture the continuous nature of tracer uptake. Future research should explore more nuanced interpretations of PET data, including the potential for quantitative tracer uptake analysis to refine treatment strategies further.

The findings from the 3TMPO cohort study underscore the critical role of triple-tracer PET imaging in understanding the complexity of mCRPC. The high prevalence of IIH and the associated poor prognosis for patients with certain imaging phenotypes highlight the importance of incorporating advanced molecular imaging into the clinical management of mCRPC. By offering a non-invasive means to characterise tumour biology across multiple metastases, triple-tracer PET imaging has the potential to guide more precise and personalised treatment strategies, ultimately improving outcomes for patients facing this challenging disease. As molecular imaging continues to evolve, it will play an increasingly central role in the era of precision oncology, where treatment decisions are tailored to the unique characteristics of each patient's cancer.

**Source Credit:** [Journal of Nuclear Medicine](#)

**Image Credit:** [iStock](#)

Published on : Tue, 1 Oct 2024