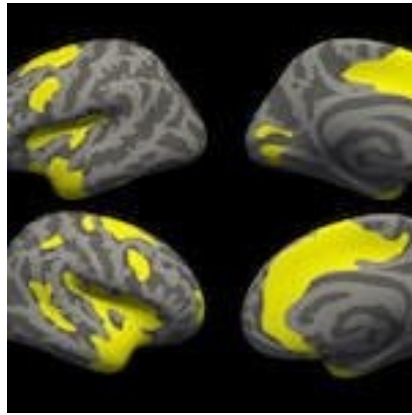




## #RSNA18: MRI finds depression and anxiety brain pattern



In a study presented at the annual meeting of the Radiological Society of North America (RSNA) in Chicago, researchers have uncovered a common pattern of structural similarities and differences in the brains of people suffering from depression and social anxiety using MRI.

The study compared major depressive disorder (MDD) and social anxiety disorder (SAD); two conditions with some similar clinical symptoms indicating the mental disorders may present similar brain mechanisms.

Few studies have directly compared the brain structural effects of the two disorders, said author of the study Dr. Youjin Zhao from Sichuan University in Chengdu, China.

**You may also like:** [PET imaging tool measures synaptic loss in Alzheimer's disease](#)

For the study the researchers analyzed high-resolution images from 37 patients suffering from depression (MDD), 24 patients with social anxiety disorder (SAD) and 41 healthy control individuals.

Using MRI, Dr. Zhao and co-author Dr. Su Li examined variations in the brain's grey matter, focusing on the thickness of the cortex, which is the outer layer of the cerebrum, or principal part of the brain. They found that both MDD and SAD patients displayed grey matter abnormalities in the salience (brain regions that determine which stimuli get our attention) and dorsal (affects focus and attentiveness) attention networks compared to the healthy control patients.

Sufferers of MDD, commonly referred to as depression, can be completely debilitated, losing interest in everything they once enjoyed and can find it difficult to even get out of bed. MDD affects about 16 millions people in the U.S.

Equally severe, social anxiety disorder (SAD) makes people intensely fear they are being watched and judged leading to symptoms that disrupt their daily life, making it difficult to develop and maintain social and romantic relationships. Social anxiety disorder affects about 15 million adults in the U.S.

The differences they discovered between healthy subjects and patients with depression and social anxiety disorder were the thickening or thinning of the cortex. Both MDD and SAD patients displayed cortical thickening in the brain region integral to perception and self-awareness (insular cortex) compared to the healthy subjects.

"Our findings provide preliminary evidence of common and specific gray matter changes in MDD and SAD

patients," Dr. Zhao said. "Future studies with larger sample sizes combined with machine learning analysis may further aid the diagnostic and prognostic value of structural MRI."

Dr. Zhao said the exact correlation between the clinical manifestations of MDD and SAD and cortical thickening in brain regions like the part of the brain associated with emotion (anterior cingulate cortex) is still unclear.

"First, it is possible that a greater cortical thickness may reflect a compensatory mechanism that is related to inflammation or other aspects of the pathophysiology," said Dr. Zhao. "Second, greater anterior cingulate cortical thickness could be the result of both the continuous coping efforts and emotion regulation attempts of MDD and SAD patients."

According to Dr. Zhao, they also found that alterations in the brain within the visual recognition network region may be related to decreased selective attention and working memory in patients with depression. In the patients with social anxiety disorder, the researchers also determined disorder-specific involvement of the brain's "fear circuitry".

"The visual recognition network is involved in emotional facial processing, which is crucial for social functioning," she said. "Depression has been associated with structural alterations in these regions."

Source: [RADIOLOGICAL SOCIETY OF NORTH AMERICA](#)

Image Credit: RSNA

Published on : Tue, 27 Nov 2018