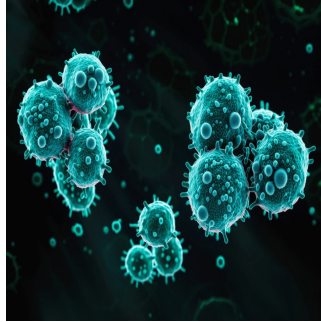

Role of Artificial Intelligence in Preoperative Detection of Lung Metastases



Lung metastases are a significant concern in patients with cancer, often indicating a poor prognosis and influencing the course of treatment. Accurate detection of pulmonary metastases is vital for effective surgical planning and improving patient outcomes. Preoperative computed tomography (CT) scans serve as a cornerstone for diagnosing these metastatic nodules, but they come with limitations in sensitivity, mainly when relying solely on visual assessment by radiologists. Recent advances in artificial intelligence (AI) and deep learning (DL) offer new possibilities for enhancing nodule detection. A recent review published in the *European Journal of Radiology* retrospectively evaluated the effectiveness of an AI-based system in detecting lung metastases from preoperative CT scans, comparing its performance against unassisted radiologists and exploring the potential for earlier detection of nodules.

Methodology and AI Application in Nodule Detection

The study analysed a cohort of 167 patients who underwent lung metastasectomy between 2016 and 2020 using their preoperative CT scans. The AI system employed, "Veye Lung Nodules," utilised a DL-based computer-aided detection (CAD) algorithm with convolutional neural networks (CNNs) to identify lung nodules. This algorithm works by processing CT scans and automatically detecting nodules based on a threshold of 3 mm, which helps distinguish between true nodules and false positives. A key component of this study was to compare the sensitivity of nodule detection between three groups: unassisted radiologists, AI alone, and a combination of radiologists and AI (RAD + AI).

To assess the ground truth for the study, a consensus reading by two radiologists identified all nodules visible on CT scans, confirmed by the pathology report post-resection. This process ensured that each nodule identified in surgery could be evaluated retrospectively for its detectability on the CT scans. Various nodule characteristics, such as size, location in the lung, and contact with surrounding structures, were analysed by both AI and radiologists to understand their impact on detection. The ultimate goal was to determine whether the AI could enhance the accuracy and sensitivity of preoperative lung nodule detection and identify any potential benefits for earlier intervention.

Results: Enhanced Sensitivity and Early Detection with AI

The study found that AI significantly increased the sensitivity of detecting resected nodules compared to unassisted radiologists. AI detected an average of 4 nodules per CT scan, with a high accuracy of 97% true nodules, resulting in a minimal false positive rate. While unassisted radiologists achieved an 80.4% sensitivity in nodule detection across all CT scans, the AI system alone improved this to 85.9%. However, when combining radiologist evaluation with AI assistance (RAD + AI), the sensitivity increased significantly to 92.4%. This marked improvement suggests that AI can serve as a valuable second reader, enhancing the detection of nodules that may have otherwise been missed.

In the temporal analysis, AI demonstrated its capacity for earlier detection of lung nodules. For patients who had multiple CT scans before their surgery, AI detected nodules on earlier scans in 47.4% of cases where radiologists initially missed them. This earlier detection was crucial for identifying metastatic lung nodules, potentially leading to timelier surgical interventions and better patient outcomes.

Interestingly, the study noted specific characteristics that influenced nodule detectability by radiologists and AI. For example, nodules with vascular contact were less likely to be detected by radiologists, while cavitation and pleural contact posed challenges for AI detection. The findings highlight that AI's enhanced sensitivity was most beneficial in detecting nodules with certain characteristics, complementing radiologists' visual analysis.

Implications for Clinical Practice and Future Development

© For personal and private use only. Reproduction must be permitted by the copyright holder. Email to copyright@mindbyte.eu.

The study underscores the clinical benefits of using AI to help radiologists make a preoperative CT assessment of lung metastases. The higher sensitivity of RAD + AI suggests that AI-assisted radiology could be integrated into clinical workflows to improve the detection of lung nodules, ultimately leading to more comprehensive treatment planning. Since early detection and accurate characterisation of nodules are critical for patient prognosis, implementing AI may reduce the chances of overlooking metastases, allowing for more aggressive and targeted therapeutic strategies.

Moreover, the study's results suggest a broader shift towards adopting AI-based technologies in radiological practice. The DL-CAD system enhances nodule detection and minimises the burden on radiologists by reducing the need for exhaustive visual assessments. The minimal false-positive rate in this study also supports the feasibility of integrating such technology without overwhelming radiologists with unnecessary follow-ups on false findings.

Future developments in AI-based nodule detection should focus on improving the algorithm's ability to identify nodules with complex characteristics, such as those with cavitation or pleural contact. Further research could also explore how AI performance varies across patient demographics and nodule types, providing deeper insights into optimising these systems for varied clinical scenarios.

Integrating AI-based CAD systems in the preoperative assessment of lung metastases has significantly improved nodule detection sensitivity. The combination of AI assistance with radiologist evaluation results in a notable increase in identifying resectable nodules, offering the potential for earlier detection and improved surgical outcomes. The study's findings highlight the transformative role of AI in enhancing the accuracy and efficiency of radiological practice, particularly in the context of cancer care. As AI technologies evolve, their application in preoperative imaging assessment will likely become a standard practice, aiding radiologists and improving patient management. Continued refinement and validation of these tools will further enhance their effectiveness, ultimately contributing to better prognosis and treatment strategies for patients with metastatic lung disease.

Source: [European Journal of Radiology](#)

Image Credit: [iStock](#)

Published on : Tue, 1 Oct 2024