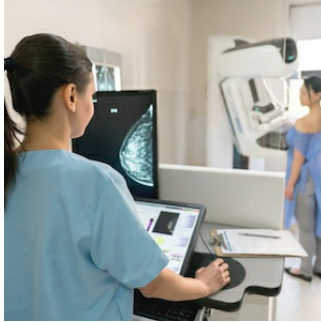


PET/MRI Pinpoint Notable Breast Cancer Biomarkers



Researchers have pinpointed breast cancer biomarkers that have the potential to indicate malignancy presence and risk.

A research team from [Memorial Sloan Kettering Cancer Center](#) in New York compared healthy contralateral breast tissue of patients with malignant breast tumours and benign breast tumors. They found that PET/MRI imaging could assess multiple biomarker differences that could impact risk-adapted screening and risk-reduction strategies in clinical practice.

You might also like: [Retinal Imaging Biomarker for Early Alzheimer's](#)

Early detection of malignancy is critical in breast cancer for best prognosis and survival. Screening has been successful in decreasing breast cancer patient mortality but is limited for women with dense breast tissue.

"Such shortcomings warrant further refinements in breast cancer screening modalities and the identification of imaging biomarkers to guide follow-up care for breast cancer patients," said Doris Leithner, MD, research fellow.

The study included 141 patients with imaging abnormalities on mammography or sonography on a tumour. The patients underwent combined PET/MRI of the breast with dynamic contrast-enhanced MRI, diffusion-...

The study included 141 patients with imaging abnormalities on mammography or sonography on a tumor-free contralateral breast. The patients underwent combined PET/MRI of the breast with dynamic contrast-enhanced MRI, diffusion-weighted imaging (DWI) and the radiotracer 18F-FDG.

Several imaging biomarkers were recorded in the tumor-free breast in all patients with differences analysed by two independent readers.

The readers assessed 100 malignant and 41 benign lesions. In the contralateral breast tissue, background parenchymal enhancement and breast parenchymal uptake were decreased and showed significant differences between patients with [benign and malignant lesions](#). The difference in fibroglandular tissue came close but did not reach significance, and the mean apparent diffusion coefficient did not differ between the groups.

"Based on these results, tracer uptake of normal breast parenchyma in 18F-FDG PET might serve as another important, easily quantifiable imaging biomarker in breast cancer, similar to breast density in mammography and background parenchymal enhancement in MRI," Leithner explained. "As hybrid PET/MRI scanners are increasingly being used in clinical practice, they can simultaneously assess and monitor multiple imaging biomarkers -- including breast parenchymal uptake -- which could consequently contribute to risk-adapted screening and guide risk-reduction strategies."

Source: [Society of Nuclear Medicine and Molecular Imaging](#)

Image credit: iStock

Published on : Tue, 28 Jan 2020