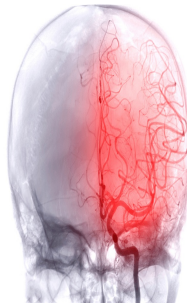

Outcomes of Basilar Artery Occlusion: Impact of Ischaemic Stroke Topography



Basilar artery occlusion (BAO) is a critical condition that can lead to significant morbidity and mortality. It is primarily caused by either embolism or basilar stenosis (BS), which results from atherosclerosis. The location and type of occlusion play a crucial role in determining the stroke's topography and, consequently, its outcome. BAO can be categorised into BAO due to embolism (BAOE) and BAO due to underlying stenosis (BAOS). Patients with BAOS tend to have more proximal occlusions in the basilar artery (BA) compared to BAOE. This distinction in the occlusion site leads to different patterns of infarcts, particularly affecting the brainstem. This article explores the impact of ischaemic stroke topography on early clinical outcomes in BAO, focusing on how infarct patterns and aetiology contribute to prognosis and recovery.

Infarct Topography and Early Clinical Outcome

The topography of the infarct, or its location within the brainstem and associated areas, is crucial in determining early clinical outcomes in patients with BAO. In particular, poor clinical outcomes are associated with infarcts affecting the medulla oblongata, inferior pons, superior pons, and occipital lobes. The brainstem is an anatomically dense and functionally significant area, housing critical motor, sensory, and vegetative pathways. Damage to these structures, particularly the inferior brainstem, is more likely to result in severe disability. Furthermore, patients with BAOS often experience larger infarct volumes in the inferior brainstem due to the more proximal location of the occlusion. This proximal occlusion tends to affect the medulla oblongata and pons more extensively, resulting in significant neurological deficits and worse early outcomes.

Role of Aetiology in Clinical Outcomes

BAOS and BAOE present with different infarct patterns and outcomes. Patients with BAOS, characterised by proximal occlusions and an association with atherosclerotic stenosis, tend to have worse outcomes compared to those with BAOE, where occlusions are more distal. The higher incidence of inferior brainstem infarcts in BAOS patients is a primary factor in their poorer prognosis. These proximal occlusions in BAOS compromise blood flow to the brainstem's critical areas more severely than the more distal occlusions observed in BAOE. Moreover, the likelihood of successful reperfusion through endovascular treatment is lower in BAOS than in BAOE, contributing to poorer early outcomes. This difference in the efficacy of reperfusion is likely due to the greater difficulty in achieving vessel recanalization in stenotic occlusions.

Implications for Treatment Strategies

The differing clinical outcomes in BAOS and BAOE highlight the importance of personalised treatment strategies based on stroke aetiology and topography. Given the poorer outcomes associated with BAOS, aggressive endovascular treatment may be warranted. Interventions such as stent placement may improve reperfusion success in these cases, potentially mitigating the unfavourable outcomes associated with inferior brainstem infarcts. Additionally, early recognition of the underlying aetiology (whether BAOS or BAOE) can guide treatment plans, including the anticipation of longer procedural times, consideration of stenting, and administration of antithrombotic therapy. The presence of underlying stenosis should be treated as a distinct entity, and these patients may benefit from more aggressive interventions to address the proximal occlusions effectively.

The topography of ischaemic infarcts is pivotal in determining early clinical outcomes in BAO. Inferior brainstem and occipital infarcts are associated with poor outcomes, particularly in patients with BAOS who experience proximal occlusions. The differences in the site and extent of infarcts between BAOS and BAOE emphasise the need for tailored treatment approaches. For patients with BAOS, aggressive endovascular interventions may improve reperfusion rates and subsequently reduce the likelihood of poor outcomes. Understanding the impact of ischaemic stroke topography on clinical outcomes is essential for optimising treatment and improving prognosis in patients with BAO.

Source: [European Radiology](#)

Image Credit: [iStock](#)

Published on : Mon, 7 Oct 2024