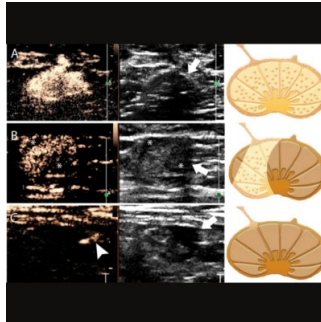


Nomogram Integrates CEUS & Grayscale US to Predict Lymph Node Metastasis



Axillary lymph node (ALN) metastasis is a crucial factor in predicting breast cancer prognosis. Sentinel lymph node (SLN) biopsy is the standard procedure for early breast cancer cases with preoperative negative ALN. A nomogram that integrates lymphatic contrast-enhanced ultrasound (CEUS) and grayscale ultrasound (US) findings of SLNs has been published in [Insights into Imaging](#) to preoperatively identify early breast cancer patients with either low or high axillary tumour burden. This approach is particularly relevant in the Z0011 era and can assist in multidisciplinary treatment decision-making for these patients.

Challenges in SLN Evaluation in the post-Z0011 era

The ACOSOG Z0011 study indicated that complete ALN dissection is unnecessary for T1–2 breast cancer patients with fewer than three involved ALNs who undergo breast-conserving surgery and whole-breast radiotherapy. Approximately 25–35% of clinically node-negative patients have nodal metastases, and about 10% have three or more metastatic ALNs. Identifying three or more metastatic ALNs preoperatively can lead to neoadjuvant systemic treatment or direct ALN dissection. Ultrasound (US) is the primary tool for axillary evaluation in newly diagnosed breast cancer patients. While preoperative US-guided biopsy can detect axillary metastasis, it lacks accuracy in identifying high metastatic ALNs. Contrast-enhanced (CE) lymphatic US is a safe and effective method for detecting SLNs in cancer patients. Despite the potential of CE lymphatic US, its enhancement patterns show limited diagnostic value for detecting three or more metastatic ALNs, with specificity and accuracy being 34.2% and 37.9%, respectively. Grayscale US could complement enhancement patterns in evaluating metastatic ALNs. However, combining enhancement patterns and grayscale US findings for predicting three or more LN metastases is not well-established. Given these challenges, the study aims to develop a nomogram using clinicopathologic data, CE lymphatic US, and grayscale US findings of SLNs to preoperatively predict three or more metastatic ALNs in early breast cancer patients. This nomogram could assist clinicians in stratifying patients and guiding treatment decisions.

Nomogram offers promising SLN identification rates

Women with newly diagnosed clinical T1–2 invasive breast cancer and no palpable ALN (cN0) were recruited for axillary lymphatic US evaluation, excluding those allergic to US contrast agent, with a history of ipsilateral breast cancer surgery or radiotherapy, those who received neoadjuvant chemotherapy, and those under 18 years old. At Centre 1, out of 282 eligible women, 179 formed the development cohort and 90 formed the internal validation cohort. Five were excluded due to failed SLN identification on lymphatic US. The SLN identification rates were 98.2% for CE lymphatic US, 97.7% for Sonovue, and 99.0% for Sonazoid. At Centre 2, out of 207 recruited women, 197 formed the external validation cohort after excluding seven for similar reasons. The SLN identification rates were 98.5% for CE lymphatic US, 99.0% for Sonovue, and 97.9% for Sonazoid. No adverse reactions to ultrasound contrast were reported. The cohorts were comparable in clinical T stage, tumour histologic type, tumour size, axillary surgery type, SLN biopsy results, and ALN pathologic status. However, they differed in age, histologic grade, lymphovascular invasion, hormone receptor status, breast surgery type, contrast agent used, mean number of SLNs identified by CE lymphatic US, and blue dye and ICG usage.

Nomogram Performance and Clinical Relevance in the Post-Z0011 Era

In the post-Z0011 era, there's a growing need for a reliable imaging method to accurately predict ≥ 3 metastatic ALNs in clinical T1-2N0 breast cancer. This study developed a nomogram combining lymphatic and grayscale US findings of SLNs to predict ≥ 3 metastatic ALNs. The nomogram demonstrated good discriminability (AUC, 0.91 and 0.87) and calibration (calibration slope, 1.0) in validation cohorts, with a specificity of 97.5–98.3% and a positive predictive value of 66.7% at a threshold of 40%. This nomogram is particularly relevant for the post-Z0011 era, potentially guiding neoadjuvant systemic treatment or direct ALN dissection. However, it had a low sensitivity of 33.3%, possibly missing patients with high tumour burden. False positives can occur due to inhomogeneous or nonenhancement on CE lymphatic US, and enhancement patterns can be affected by various factors, including tissue characteristics and lymphatic pressure. Radiomics data and artificial intelligence could further enhance diagnostic efficiency in SLN status diagnosis. Two different contrast agents, Sonovue and Sonazoid, were used for SLN identification, both showing potential without significant differences in SLN detection or diagnosis of metastatic ALNs. Although axillary metastases can be related to various clinicopathologic characteristics, in this study, only US image findings correlated with ≥ 3 metastatic ALNs.

The study had limitations, including the inclusion of only one SLN per patient identified by CE lymphatic US, potential influence of previous biopsy procedures on lymphatic vessel display, and operator-dependent interpretation of CE lymphatic US images. This nomogram combining

CE lymphatic US and grayscale US findings of SLNs can preoperatively identify early breast cancer patients with low or high axillary tumour burden, making it valuable for multidisciplinary treatment decision-making in the Z0011 era.

Source & Image Credit: [Insights into Imaging](#)

Published on : Fri, 5 Apr 2024