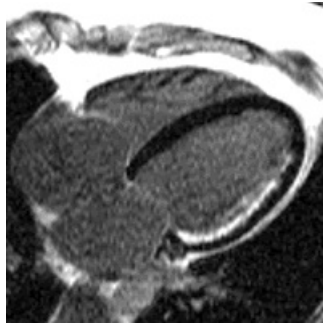


## MRI Saves Heart Muscle



---

Researchers using cardiac MRI discovered that thinned non-contracting heart muscle caused by a heart attack can potentially improve in function and be reversed after cardiac bypass surgery. This was found to be true in a small number of patients who had limited scarring of the heart, as detected by MRI. The findings appear in the March 6 issue of JAMA.

"Traditional thinking is that heart muscle thinned out by a heart attack was dead muscle and that nothing could be done about it," said Dr. Dipan Shah, a cardiologist with the Methodist DeBakey Heart & Vascular Center in Houston and the paper's lead author. "This study shows MRI gives us a much clearer picture and a better ability to help patients who otherwise might be rejected for cardiac bypass surgery. I believe this represents a potentially fundamental shift in our understanding of cardiac disease."

Shah says a heart attack deprives a portion of the heart muscle from much needed oxygen and nutrients. As the muscle cells die off they are replaced by collagen, which causes the wall to thin and prohibits the heart from pumping effectively. A normal heart wall is anywhere from 7 to 10 millimetres in thickness, while one that has thinning is 5-1/2 millimetres or less.

"Other viability tests measure viability indirectly, or can image only the amount of viable tissue and not the amount of scarring. Many times the thinned areas are declared dead because the amount of viable tissue is small," Shah said. "MRI gives us the ability to get precise detail on the amount of viable as well as scarred myocardium and thus accurately determine if a patient has potential to recover contractile function and reverse wall thinning."

The study looked at 1,055 patients at Duke University, Northwestern University and at The Heart Group in Nashville, TN. with stable coronary disease who were undergoing evaluation for myocardial viability. Of those patients, 201 had wall thinning but very limited scarring. Of patients that went on to undergo cardiac bypass surgery and returned for a follow up MRI, all with limited scarring demonstrated improvement in contractile function and a reversal of wall thinning.

"This study distinguishes MRI from other techniques to assess myocardial viability because it detected that wall thinning can occur in the setting of limited scarring and is potentially reversible. "This type of testing could potentially benefit many patients who, in the past, would be turned down for cardiac bypass surgery because they had wall thinning."

Published on : Wed, 6 Mar 2013