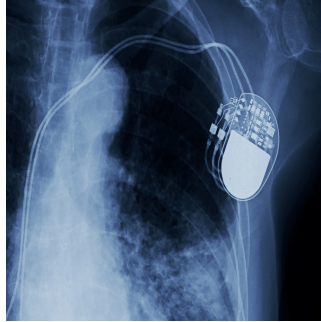


---

## MRI in Patients with Abandoned Cardiovascular Implantable Devices



---

Current guidelines on MRI for patients with cardiac implantable electronic devices (CIEDs) and abandoned leads or fragments vary between regions. In the United States, the Heart Rhythm Society lacks clear recommendations due to insufficient data, while European guidelines offer a class IIb recommendation, suggesting MRI if benefits outweigh risks, without specifying harm probability. Patients with abandoned leads face risks from unpredictable lead tip heating during MRI and potential CIED-related complications. However, studies using specific protocols or after CIED generator removal show no adverse events or myocardial injury. In vitro data suggest lead length and orientation affect MRI heating, but clinical implications remain unclear. [This study published in Radiology: Cardiothoracic Imaging](#) aims to assess lead orientation and length effects on clinical outcomes and CIED function in patients undergoing 1.5-T MRI.

### Safety and Protocol Adherence in 1.5-T MRI of Patients with Abandoned Implantable Device Leads

This retrospective study analyzed patients with cardiac implantable electronic devices (CIEDs) and abandoned leads or lead fragments who underwent clinically indicated 1.5-T MRI at two academic medical centers within an integrated health care system. The study, approved by the institutional review board and compliant with Health Insurance Portability and Accountability Act regulations, included consecutive patients from March 2014 to July 2020, with waived requirement for written informed consent.

Patients with non-MRI conditional CIEDs (abandoned leads or fragments) followed a predefined protocol. Before MRI, chest radiography identified lead positions. CIED interrogation was performed, and settings were adjusted to asynchronous or nonpacing modes based on pacemaker dependence. MRI was conducted using 1.5-T machines with specific absorption rate <2 W/kg, adjusted as necessary. Patient vital signs and cardiac monitoring were supervised throughout by qualified personnel. Post-MRI, devices were reinterrogated and reset to pre-MRI settings.

Lead orientation (categorized based on radiographic appearance), lead length (measured from radiographs), and MRI specifics (anatomic region imaged, duration) were assessed for associations with significant changes in capture threshold, sensing, or lead impedance using generalized estimating equations to account for repeated measures. Statistical significance was set at  $P < .05$  using Stata software, version 17.

### Clinical Outcomes of 1.5-T MRI in Patients with Abandoned CIED Leads

Eighty patients with abandoned cardiac implantable electronic device (CIED) leads (67 pacemaker leads, 27 implantable cardioverter defibrillator leads) or lead fragments (21 pacemaker lead fragments, 2 implantable cardioverter defibrillator lead fragments) underwent 107 1.5-T MRI examinations across 126 body regions. Patients with abandoned leads were older than those with fragments (median age 74 vs 66 years). MRI studies covered various body regions, with differences observed between abandoned leads and fragments in MRI distribution but not in duration. No deaths, significant arrhythmias, or adverse events occurred within 30 days post-MRI. Changes in lead parameters were noted in three patients, managed by device reprogramming. Statistical analysis found no association between lead orientation, lead length, MRI specifics, and significant changes in capture threshold, sensing, or lead impedance.

### Clinical Considerations of 1.5-T MRI in Patients with Abandoned CIED Leads

The study involved 80 patients with a total of 126 MRI examinations across various body regions, including brain, neck, chest, abdomen, and extremities. Patients had either abandoned pacemaker leads or fragments of implantable cardioverter defibrillator (ICD) leads. Notably, there were no deaths, significant arrhythmias, or adverse events reported within 30 days following any of the MRI procedures.

Changes in CIED settings were observed in 2.8% of cases, affecting parameters such as capture threshold and sensing, but these changes did

not necessitate lead or device revision and were managed through reprogramming.

The study highlighted theoretical factors influencing the risk profile during MRI, such as lead type (endocardial vs epicardial), lead termination condition, and proximity to the MRI isocenter. It emphasised that despite these theoretical risks, clinical outcomes remained favourable.

The MRI protocols employed measures to mitigate potential risks, including careful management of specific absorption rate, use of appropriate coils, and selection of non-chest landmarks for imaging, aiming to minimize interactions between abandoned leads or fragments and the MRI magnetic field.

Limitations of the study included its retrospective design, which may have led to incomplete capture of adverse events, and the lack of direct assessment of lead heating. Nevertheless, the study contributes to the growing body of evidence supporting the safety of 1.5-T MRI in patients with abandoned CIED leads or lead fragments.

In conclusion, despite historical concerns and insurance reimbursement challenges, the study suggests that MRI may be considered for patients with abandoned leads when clinically indicated, as alternatives may offer less diagnostic accuracy or higher procedural risks. The authors advocate for larger prospective studies to further validate these findings and expand access to MRI in this patient population.

**Source:** [Radiology: Cardiothoracic Imaging](#)

**Image Credit:** [iStock](#)

Published on : Tue, 18 Jun 2024