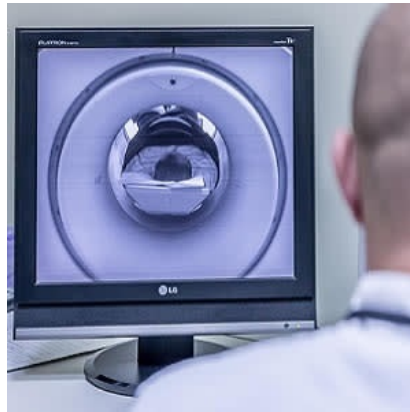




Importance of intracranial vessel wall MRI



Vessel wall magnetic resonance imaging (VW-MRI) is a modern imaging technique with expanding applications in the characterisation of intracranial vessel wall pathology. Radiologists need to be familiar with this important imaging technique, given its increasing use and future relevance to everyday practice, says a review article in the journal *World Neurosurgery*.

Imaging of the intracranial vessel wall is challenging owing to the small calibre and tortuosity of the intracranial vessels. Visualising the normal and pathological intracranial vessel wall requires very high spatial and contrast resolution to depict the inner and outer layers. The wall thickness of a normal middle cerebral artery (MCA) is estimated to vary between 0.2 and 0.7 mm.

According to the article, VW-MRI provides a useful adjunct to conventional intracranial vessel imaging and offers a novel opportunity for differentiation of intracranial arterial pathologies. Compared with other traditional luminal imaging techniques, the article notes, VW-MRI has been found to be more precise in determining the degree of stenosis and nonstenotic, nonflow-limiting atherosclerotic lesions.

"For example, arterial stenoses may result from a number of different etiologies and may benefit from further morphological classification with VW-MRI," the article explains. "As a result, VW-MRI can improve patient care by increasing diagnostic accuracy and reducing diagnostic delays."

Careful examination of the normal healthy vessel wall is important to allow a comparison of the suspected diseased vessel to the normal internal control. Vessel wall thickness and remodelling are biomarkers of artery status. "A healthy vessel wall," the article says, "is regular, uniformly thick, and does not enhance."

Prominent vessel wall enhancement occurs in patients with acute ischaemic stroke with intracranial atherosclerotic stenosis during the acute phase (first 4 weeks), with contrast enhancement diminishing over time. Plaque enhancement, according to the article, can be used as a marker of the stability of a plaque.

"Intraplaque haemorrhage is considered the most important imaging feature of atherosclerotic plaques and is associated with plaque vulnerability and associated complications based mostly on extracranial studies," the article says.

Despite the paucity of evidence, some reports suggest that VW-MRI may have the capacity to identify a ruptured intracranial aneurysm from among multiple potential culprit aneurysms. A ruptured aneurysm usually demonstrates a thickened vessel wall with enhancement.

VW-MRI can be used to identify vessel wall inflammation (vasculitis) and to measure wall thickness in unruptured aneurysms. However, as the article points out, the utility of VW-MRI for aneurysms requires further study to establish its value.

VW-MRI also may have a role, albeit a limited one, in the diagnosis of intracranial pathologies in children. Periarterial enhancement is a normal finding in paediatric imaging. VW-MRI is a noninvasive investigation without ionising radiation, making it advantageous in paediatric patients, and further studies are needed.

Scan time remains an important consideration when performing VW-MRI. After considering the available imaging resources, a pragmatic trade-off between scan time, number of sequences, coverage, and sufficiency of spatial and contrast resolution must be negotiated, the article says.

Further, optimisation of techniques, high-field (3-T) scanner availability, and access to relevant scan sequences remain key factors limiting the widespread clinical application of VW-MRI.

"Nonetheless, the ability to provide new information on a wide spectrum of disease processes makes VW-MRI clinically important, and this technique holds great future research potential," the article concludes.

Source: [World Neurosurgery](#)

Image Credit: Pixabay

Published on : Tue, 24 Apr 2018