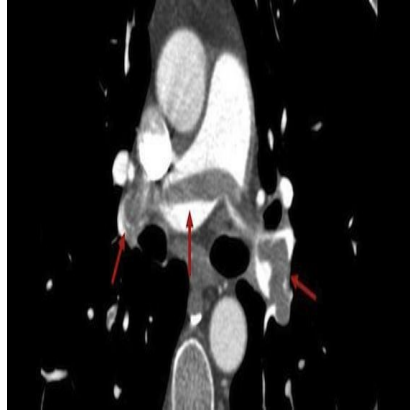




Has CT Scanning Caused Overdiagnosis of Pulmonary Emboli?



A recent article in BMJ looks at overdiagnosis of pulmonary emboli in the context of increasing use of CT scanning. Authors, Renda Soylemez Wiener, Lisa Schwartz and Steven Woloshin argue that the widespread availability of CT pulmonary angiography has encouraged doctors to lower their threshold for looking for pulmonary embolism in the hope of missing a silent killer.

The authors present evidence of overdiagnosis, including a large increase in incidence, reduced case fatality (in-hospital deaths among people with a diagnosis of pulmonary embolism), and a minimal decrease in mortality (deaths from pulmonary embolism in the population) suggesting that many of the extra emboli being detected are not clinically important.

Overdiagnosis may lead to an increase in complications from anticoagulation as well as Anxiety and inconvenience for patients. However, the authors acknowledge that evidence of overdiagnosis is limited as it is derived from administrative data or single institution case series. Without prospectively observing untreated patients, it is impossible to be certain which emboli are not clinically important

The authors conclude that further research is needed into which small emboli could be treated.

Published on : Mon, 5 Aug 2013