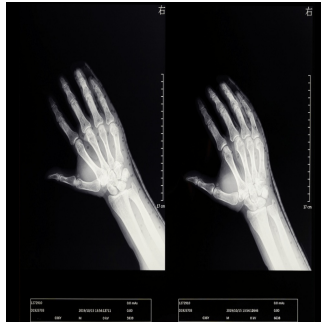


Exploring Radiopalmar Ganglion Cysts With Wrist MRI Studies



Ganglion cysts, common benign tumours with a synovial lining, are primarily found in the hand and wrist. Their exact cause isn't fully understood but could involve mucinous degeneration, trauma, or synovial herniation. While dorsal wrist ganglion cysts are well-documented, less is known about those on the palmar aspect. A previous MRI study found many asymptomatic cases, particularly at the palmar surface near specific ligaments. [This study published in European Radiology](#) explores the prevalence, morphology, and clinical relevance of these "radiopalmar" ganglion cysts in symptomatic patients using MRI.

Patient Selection and MRI Protocol in a Retrospective Wrist Study

This retrospective single-centre study, approved by the Cantonal Ethics Committee Zurich and conducted according to the Declaration of Helsinki, involved 1082 patients contributing 1233 wrist MRI scans. Patients provided written informed consent for their health data usage. The study targeted individuals with various wrist conditions, including pain (radial-sided, ulnar-sided, diffuse), trauma, arthritis, (teno-)synovitis, crystalline arthropathy, osteoarthritis, avascular necrosis/pseudarthrosis, carpal tunnel syndrome, and tumours. Exclusion criteria were prior wrist surgery, incomplete wrist depiction, and severe motion artefacts.

MRI scans were performed on 1.5-T (54.3%) and 3-T (45.7%) units using a dedicated 16-channel wrist coil. Imaging protocols included non-contrast MRI (21.5%), MRI with intravenous gadolinium contrast (49.1%), and direct MR arthrography (29.4%), tailored to clinical indications. Contrast administration details were standardised: gadolinium at 0.1 mL per kg body weight or a gadoteric acid-iodinated contrast mixture injected under fluoroscopic guidance.

Image analysis was conducted using a PACS workstation, with anonymised scans reviewed independently by two musculoskeletal radiologists with five and six years of experience. They assessed for the presence of radiopalmar ganglion cysts (RPG) based on established MRI criteria, including T1-weighted low signal and T2/PD-weighted high fluid-equivalent signal, verifying contact with joint capsules or tendon sheaths while ruling out pulsation artefacts. Morphological features such as loculation (unilocular, oligolocular, multilocular), presence of debris, and cyst dimensions in three spatial planes were meticulously recorded using PD-weighted sequences for accuracy.

Additionally, the radiologists evaluated each MRI for potential concurrent pathologies (e.g., SLL tears, bone marrow oedema, arthritis) that could contribute to wrist symptoms. Clinical data from referring physicians regarding wrist complaints (pain, swelling, motion restriction) up to four weeks before MRI were also incorporated into the analysis.

Demographics and Morphological Characteristics

In this study involving 909 patients and 1053 wrists (mean age 43.4 ± 15.5 years, 602 females), 29.2% (308 wrists) exhibited radiopalmar ganglion cysts (RPG) on MRI, while 70.8% (745 wrists) did not. Although a statistically significant age difference was noted between groups (Group 1: 41.8 ± 14.9 vs. Group 2: 44.0 ± 15.6 years, $p = 0.027$), it was not clinically significant. Gender distribution and affected side showed no significant differences between groups. RPG morphology analysis revealed that all 308 RPG originated from the palmar capsule between the RSC and LRL ligaments. They were categorised as 15.9% unilocular, 30.8% oligolocular, and 53.2% multilocular, with 40.9% containing internal debris. RPG dimensions averaged 8.5 ± 5.6 mm cranio-caudally, 8.0 ± 4.1 mm medio-laterally, and 3.7 ± 2.3 mm dorso-palmar. Direct contact with anatomical structures was observed in 54.5% with the radial vascular bundle, 7.8% with the FCR tendon, and 39.9% with the FPL tendon.

Clinical Associations and Inter-reader Agreement

Patients with RPG were significantly more likely to report radiopalmar complaints (15.3% vs. 2.7% without RPG, $p < 0.001$). RPG presence correlated with a higher incidence of partial (26.6% vs. 6.0%) and complete (7.1% vs. 2.7%) tears of the SLL compared to those without RPG. However, SLL tears were not effective in differentiating symptomatic from asymptomatic patients (AUC 0.62). Analysis of other wrist pathologies (bone marrow oedema, arthritis, osteoarthritis, avascular necrosis/pseudarthrosis, carpal tunnel syndrome, tumours) showed no significant differences between groups. Dorso-palmar RPG diameter was positively correlated with radiopalmar complaints ($r_s = 0.66/0.61$ for readers 1 and 2, $p < 0.001$), suggesting a cut-off diameter of 3 mm for predicting symptom presence (AUC 0.74). Inter-reader agreement was substantial to

almost perfect for various parameters including internal debris, RPG location, and anatomical contact, ensuring robustness in measurements and assessments.

Prevalence, Morphology, and Clinical Relevance of Radiopalmar Ganglion Cysts

This study examined radiopalmar ganglion cysts (RPG) in wrist MRI findings, revealing a prevalence of 29% among patients, with 85% of cases being asymptomatic regarding radiopalmar complaints. Notably, RPGs' dorso-palmar diameter was associated with symptomatic presentation, particularly when exceeding a 3 mm threshold.

Comparing the RPG prevalence findings to previous studies, this cohort's rate slightly exceeded general wrist ganglion cyst rates (19%) reported in MRI studies. However, specifics on radiopalmar localisation were lacking in those studies. Conversely, higher RPG rates were observed in paediatric cohorts (36–56%), suggesting possible age-related variations in ganglion prevalence. Although the RPG group was younger than the non-RPG cohort, this difference lacked clinical significance, questioning age as a determinant for RPG presence. Studies on asymptomatic populations have described simpler ganglion cyst morphology compared to these findings, where more than half of RPGs were multilocular with internal debris, likely influenced by symptomatic patient focus.

RPG dimensions in the study were comparable to previous findings, with mean diameters of 8.5 mm (cranio-caudal), 8.0 mm (medio-lateral), and 3.7 mm (dorso-palmar), consistent with reported values for wrist ganglia. Despite the predominance of asymptomatic RPGs, symptomatic presentations were significantly higher in RPG patients (15% vs. 3%), not clearly differentiated by RPG's anatomical contacts or concurrent SLL tears. Notably, dorso-palmar RPG diameter > 3 mm correlated positively with symptoms, suggesting potential clinical relevance in decision-making for RPG management.

Furthermore, the findings highlighted a higher prevalence of SLL tears among RPG patients, albeit without discriminatory utility in symptomatic identification. Theoretical links between ganglion cysts and ligamentous injuries, especially the SLL, were suggested but remain debated among existing literature.

Several study limitations merit consideration, including its retrospective design, single-centre approach, and reliance solely on MRI for RPG diagnosis without surgical validation. Variability in MRI protocols and equipment further challenges result generalizability, particularly in detecting SLL tears. Future studies addressing these limitations could provide deeper insights into RPG pathogenesis and treatment implications. RPGs are common incidental findings in wrist MRI, predominantly asymptomatic. However, RPG size, particularly dorso-palmar diameter, may influence clinical decisions, highlighting the need for cautious management strategies to avoid unnecessary interventions.

Source Credit: [European Radiology](#)

Image Credit: [iStock](#)

Published on : Thu, 4 Jul 2024