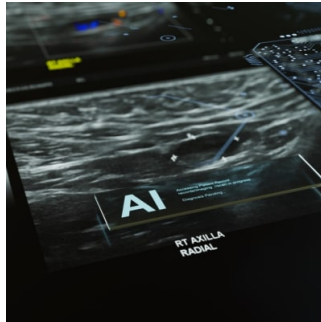


---

## ECR 2024 Day 1: Radiomics and Artificial Intelligence



---

During a workshop on research presentations at ECR, authors from around the world shared recent advancements in studies exploring the association between AI and radiomics.

### **Handcrafted radiomics, deep radiomics and transcriptomics data provide complementary and potentiating prognostic information in soft-tissue sarcoma patients**

Amandine Crombé (France) presented her retrospective single-centre study aiming to identify subgroups of soft-tissue sarcoma (STS) patients using handcrafted and deep radiomics, to understand them, and investigate their impact on metastatic relapse-free survival (MFS).

The study, conducted at a sarcoma centre between 2008 and 2020, examined adults with locally-advanced soft tissue sarcomas (STS) using contrast-enhanced MRI scans. Researchers extracted radiomics features and employed neural networks to reveal deep radiomics features. They analysed gene expression and constructed classifications based on radiomics and RNA sequencing data. Three distinct radiomics classifications were identified, which correlated with prognostic radiological features. Additionally, certain classifications were associated with metastasis-free survival (MFS). Combining these classifications improved prognostic accuracy. Molecular analysis highlighted dysregulated genes and pathways linked to tumorigenesis and immune response. The study underscores the significance of radiomics in understanding STS complexity and enhancing predictive capabilities.

### **CT lung cancer screening: pricing and cost-saving potential for deep learning computer-aided lung nodule detection software**

Mathias Prokop (Netherlands) explored the cost-effectiveness of commercial deep learning computer aided detection (DL-CAD) systems in different modes of use to maximise cost savings and identify the most cost-effective mode for lung cancer screening.

The study evaluates the use of DL-CAD (Deep Learning-Computer Aided Detection) in lung cancer screening across the US, UK, and Poland. It compares radiologist reading times with and without DL-CAD, considering costs associated with radiologist time. Results show a reduction in reading time when DL-CAD is used concurrently or as a prescreening reader, but a slight increase when used as a second reader. The study calculates the minimum number of CT scans needed to make DL-CAD cost-effective. It concludes that DL-CAD needs to be used in high-workload settings or priced below €6 per case to reach cost-effectiveness, with prescreening reading showing the most potential for cost savings. However, the study acknowledges limitations in not considering downstream costs related to diagnosis and treatment.

### **A fully automated deep learning model based on multiparametric imaging for predicting tumour recurrence of locally advanced rectal cancer after neoadjuvant chemoradiotherapy: a multicenter study**

Zonglin Liu (China)

The study aimed to create and validate an automated deep learning model using multimodal MRI data to predict disease-free survival (DFS) in locally advanced rectal cancer (LARC) patients treated with neoadjuvant therapy. Data from 462 patients across three centres was used, with a multitask model developed to simultaneously perform segmentation, risk classification, and survival prediction. An attention mechanism was incorporated to enhance information extraction from the multimodal data. Results showed the model outperformed single-task models, achieving a higher AUC for risk classification and favourable metrics for segmentation and survival prediction. The study suggests multitask deep learning models could enhance personalised treatment planning for LARC patients.

### **Prognostic value of the consensus molecular subtype 4 (CMS4) predicted by multiparametric radiomics-based machine learning in colorectal cancer: a multicentre retrospective study**

© For personal and private use only. Reproduction must be permitted by the copyright holder. Email to [copyright@mindbyte.eu](mailto:copyright@mindbyte.eu).

Zonglin Liu (China)

The study aimed to explore the use of a radiomics-based machine learning approach in predicting CMS4 status (a subtype associated with poor prognosis) in colorectal cancer (CRC) patients. Data from 228 CRC cases across three centres were used, with sequencing data and baseline MRI images available. Radiomics features were extracted, and various machine learning algorithms were applied to develop predictive models. Results showed that the contrast-enhanced (CE) model outperformed the T2-weighted (T2WI) model in predicting CMS4 status. Combining the two models further improved predictive performance. The study concludes that multiparametric radiomics-based machine learning holds promise for distinguishing CMS4 from other CRC subtypes.

### **Interlesional morphological heterogeneity as a novel noninvasive prognostic biomarker**

Zuhir Elkarghali (Netherlands)

This study introduces a novel approach to assessing tumour heterogeneity using medical image analysis techniques, aiming to substitute for invasive biopsies. A pancancer cohort of 1692 CE-CT scans with confirmed diagnoses was collected, and 3D tumour segmentation was performed. Radiomic features characterizing lesion morphology were derived, and seven similarity distance metrics were used to measure morphological dissimilarity between lesions within each patient. Survival analysis showed that patients with high interlesional morphological heterogeneity had significantly different outcomes compared to those with low heterogeneity, with several distance metrics effectively stratifying patients into high- and low-risk groups. The study concludes that interlesional morphological heterogeneity, as assessed by radiomics and similarity distance metrics, strongly correlates with overall survival.

### **Clinical assessment of deep learning reconstruction-based accelerated rectal MRI**

Wenjing Peng (China)

The study aimed to clinically assess the use of deep learning reconstruction (DLR)-based rectal MRI compared to standard MRI in patients with rectal adenocarcinoma. Patients were prospectively enrolled and underwent both standard fast spin-echo (FSEstandard) and DLR-based accelerated FSE (FSEDL) protocols. Imaging quality and diagnostic performance were evaluated by radiologists, with reading efficiency also assessed. Results showed that DLR reduced acquisition time by 65% and provided higher signal-noise ratio (SNR), contrast-noise ratio (CNR), and subjective scores for various imaging aspects. FSEDL demonstrated improved T-staging accuracy, especially for junior readers, with comparable performance in other diagnostic metrics. Additionally, FSEDL shortened the diagnostic time for various assessments. The study concludes that FSEDL is clinically feasible, offering improved image quality, reading efficiency, and the potential for enhanced accuracy in T-staging, particularly for junior radiologists.

### **Radiomic analysis of PI-RADS 4 and 5 lesions detected on 3T mpMRI: role in the diagnosis of clinically significant prostate cancer**

Pietro Andrea Bonaffini (Italy) presented a monocentric retrospective study whose purpose was to identify radiomic features potentially supporting the detection of clinically significant prostate cancer (csPC) in PI-RADS 4/5 lesions detected on 3T multiparametric MRI (mpMRI) studies.

The study retrospectively analyzed patients who underwent 3T mpMRI between June 2016 and March 2021, focusing on lesions rated PI-RADS 4-5 (PI-RADS v2.1) with histopathological confirmation. Clinical and MRI parameters were collected, and radiomic features were extracted from manually contoured lesions. The best predictive multivariate model included PSA density and specific radiomic features, achieving 79% sensitivity, 80% specificity, and 79% accuracy for detecting clinically significant prostate cancer (csPC) in PI-RADS 4-5 lesions. For peripheral zone lesions, the model showed higher performance, with 86% sensitivity, 80% specificity, and 84% accuracy. The study concludes that texture and heterogeneity features extracted from mpMRI sequences improve csPC detection, particularly in peripheral zone lesions, and correlate with PSA density.

### **Imaging derived biomarkers integrated with clinical and laboratory values predict recurrence of hepatocellular carcinoma after liver transplantation**

Thi Phuong Thao Hoang (Vietnam) investigated the prognostic value of computed tomography (CT) derived imaging biomarkers in hepatocellular carcinoma (HCC) recurrence after liver transplantation (LT) and developed a predictive nomogram model.

In this retrospective study, 178 patients who underwent liver transplantation (LT) for histopathologically confirmed hepatocellular carcinoma (HCC) between 2007 and 2021 were evaluated. Baseline multiphase contrast-enhanced CT imaging features, clinical findings, and laboratory parameters were assessed to identify predictors of HCC recurrence. The rate of recurrence after LT was 17.4%. Using LASSO regression, six independent predictors of recurrence were identified, including peritumoural enhancement, multiple tumour lesions, tumour size exceeding 3 cm, elevated serum alpha-fetoprotein (AFP) levels, the presence of a tumour capsule, and a history of bridging therapies. Additionally, irregular margins, satellite nodules, and small lesions were associated with a shorter time-to-recurrence. A nomogram model incorporating these factors showed good predictive performance for HCC recurrence, with a C-index of 0.835 and high AUC values for 1-year, 3-year, and 5-year recurrence predictions. The study concludes that imaging parameters and serum AFP levels, along with treatment history, can serve as valuable biomarkers for predicting HCC recurrence post-transplantation.

### **CT texture analysis as a predictor for the genetic profile of mass-forming intrahepatic cholangiocarcinoma**

© For personal and private use only. Reproduction must be permitted by the copyright holder. Email to [copyright@mindbyte.eu](mailto:copyright@mindbyte.eu).

Angela Ammirabile (Italy)

This study aimed to investigate whether CT-based radiomics can predict genetic alterations in intrahepatic cholangiocarcinoma (ICC) non-invasively. Ninety patients eligible for systemic therapy for mass-forming ICC were included, with complete molecular profiling for FGFR2, IDH1-2, and KRAS gene alterations. Radiomic features were automatically extracted from contrast-enhanced CT images, and predictive models were built incorporating clinical and radiomic data. The study found that adding radiomic features to clinical data improved the predictive performance for FGFR2 and IDH1-2 alterations, with C-index values of 0.892 and 0.811, respectively, at internal validation. Additionally, a pure radiomic model for predicting KRAS mutations achieved a C-index of 0.862. The findings suggest that radiomic features extracted from CT scans at ICC diagnosis could reliably predict genetic status, potentially impacting therapeutic strategies.

### **CT-based radiomics of cholangiocarcinoma and peritumoural tissue improves survival prediction: development of a clinical-radiomic model**

Angela Ammirabile (Italy)

The study aimed to investigate whether textural features extracted from preoperative CT scans could enhance the prediction of survival in patients undergoing resection for intrahepatic cholangiocarcinoma (ICC). Data from 215 patients across six centres were analyzed. Radiomic features were extracted from both the tumour and peritumoural tissue regions on CT scans. Predictive models for overall and progression-free survival (OS/PFS) were developed using clinical data and radiomic features from arterial and portal phases. Results showed that the addition of radiomic features improved predictive performance, with the best model including features from both tumour and peritumoural tissue achieving a C-index of 0.764 for OS. This model performed similarly to post-operative models that included pathology data. The findings suggest that CT-based radiomics, combined with clinical data, can provide preoperative survival estimation equivalent to post-operative assessment.

### **Radiomics in colon cancer: how to identify high-risk patients**

Michela Polici (Italy)

This study aimed to develop a radiomic model to identify high-risk colon cancer using preoperative CT scans. A retrospective cohort of 300 patients with nonmetastatic colon cancer was analyzed, divided into high-risk and no-risk groups based on specific clinical factors. CT scans were segmented to extract radiomic features, and stable features were selected for further analysis. Significant features were used to build a predictive radiomic model, which achieved an AUC of 0.73. Three radiomic features correlated with disease progression in survival analysis. The study suggests that the radiomic model could effectively stratify colon cancers with high-risk disease, particularly in a preoperative setting, offering a non-invasive imaging tool for risk assessment.

**Image Credit:** [iStock](#)

Published on : Wed, 28 Feb 2024