HealthManagement
Promoting Management and Leadership

DTI Reveals Brain Network Disruption in Children with PTSD

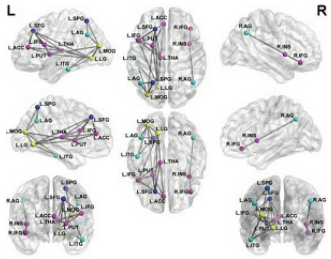

A study appearing in the journal *Radiology* has revealed that children with post-traumatic stress disorder (PTSD) experience disruptions in the structure of the neural networks in their brains. The findings could help in the development of treatments for PTSD in children.

PTSD is a serious mental health problem to the effects of which children are particularly susceptible since the neurochemical and hormonal effects associated with traumatic experiences often result in persistent alterations in brain structure and function thus affecting brain development. Early intervention is of great significance as it can prevent brain changes from developing further. Magnetic resonance imaging (MRI) is a powerful tool that can identify vulnerable patients and thus allow such interventions to start sooner.

Researchers from China and the UK used MRI to compare the brain structure of 24 patients with PTSD and 23 trauma-exposed control subjects without PTSD. All participants had experienced a disastrous earthquake in Sichuan, south central China in 2008. Diffusion tensor imaging (DTI) was used to examine the abnormalities, or lack thereof, in the map of the neural connections in the brain, i.e. the brain's connectome. DTI revealed significant structural differences between children with PTSD and children without PTSD. Patients with PTSD showed an increase in the characteristic path length and decreases in the local and global efficiency due to damage or disconnection between linked regions. Furthermore, the PTSD group demonstrated reduced nodal centralities, mainly in the default mode, salience, central executive and visual regions.

In the PTSD group, the structural connectome showed a trend toward regularisation. This shift may be a regular pattern in paediatric PTSD, as it has also been observed in previous research in the same group of patients. It is therefore a potential target for future therapeutic plans in children with the disorder. The researchers plan to perform follow-up imaging on the same patients in order to explore PTSD-associated brain changes further.

Source: Radiology

Image Credit: RSNA

Published on : Tue, 25 Oct 2016

© For personal and private use only. Reproduction must be permitted by the copyright holder. Email to copyright@mindbyte.eu.