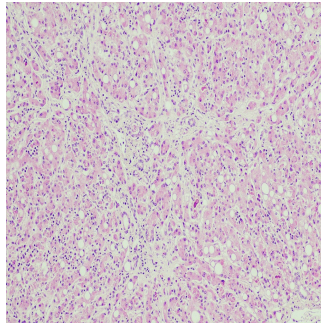


---

## Detecting Liver Fibrosis with Time-Dependent Diffusion MRI



---

Liver fibrosis, a critical health issue worldwide, can progress to cirrhosis, significantly impacting mortality rates. Fibrosis is characterised by excessive extracellular matrix deposition and is primarily driven by the behaviour of hepatic stellate cells and other liver cell types. Current clinical imaging for liver fibrosis is limited to morphologic evaluations, which do not capture detailed cellular changes. The development of time-dependent diffusion MRI has opened the door to more precise mapping of cellular microstructures, offering potential advancements in diagnosing and grading liver fibrosis. A recent review published in *Radiology* explores how time-dependent diffusion MRI provides new insights into cellular microstructural changes during fibrosis progression, as demonstrated by an animal model study.

### Advancing Fibrosis Detection

The progression of liver fibrosis to cirrhosis is marked by significant changes in hepatocyte structure and function. Traditional imaging techniques focus on morphological changes, which may only reveal the condition at advanced stages. Time-dependent diffusion MRI, however, uses diffusion gradients at varying temporal waveforms to extract diffusion spectra and tissue microstructural parameters, such as cell size, intracellular volume fraction (ICVF), and cellularity. A prospective study using a rat model of liver fibrosis induced by diethylnitrosamine (DEN) explored the effectiveness of this technique. The researchers mapped microstructural changes using the imaging microstructural parameters using a limited spectrally edited diffusion (IMPULSED) model, comparing MRI-derived measurements with histopathologic findings.

### Key Findings on Microstructural Changes and Parameter Correlations

The study found that the average cell diameter decreased as liver fibrosis progressed while ICVF and cellularity increased. This observation indicates the association of fibrotic progression with greater cellular density and structural changes in hepatocytes. The correlations between MRI-derived and pathology-derived measurements were strong, with cell diameter showing the highest correlation ( $r = 0.84$ ), followed by ICVF ( $r = 0.62$ ) and cellularity ( $r = 0.44$ ). Such data suggest that cell diameter and ICVF are reliable markers for assessing liver fibrosis stages. Notably, these microstructural parameters displayed a consistent trend across the METAVIR classification system, which grades liver fibrosis from F0 (no fibrosis) to F4 (cirrhosis).

### Implications for Liver Fibrosis Diagnosis and Grading

The study supports the potential of time-dependent diffusion MRI as a noninvasive method for diagnosing and grading liver fibrosis. By evaluating microstructural parameters, it is possible to differentiate between the stages of fibrosis, providing an accurate assessment of disease severity. This method could be particularly valuable for early diagnosis, allowing for more timely interventions and personalised treatments. Additionally, the technique could serve as a noninvasive approach to monitor treatment efficacy over time. Time-dependent diffusion MRI's ability to map cellular changes before they manifest as tissue-level abnormalities could revolutionise liver disease management by providing earlier and more precise diagnostics.

The study of liver fibrosis using time-dependent diffusion MRI reveals significant potential for the noninvasive assessment of fibrosis grading. The strong correlations between MRI-derived and pathology-derived microstructural parameters underscore the reliability of this imaging technique in detecting cellular changes. The decrease in cell diameter and increase in ICVF and cellularity are key indicators of fibrosis progression, offering valuable biomarkers for clinical assessment. With further research and development, time-dependent diffusion MRI could become a standard diagnostic tool, providing more detailed insights into the cellular microenvironment of liver fibrosis and improving patient outcomes through early detection and targeted therapies.

Source: [Radiology](#)  
Image Credit: [iStock](#)

Published on : Mon, 7 Oct 2024