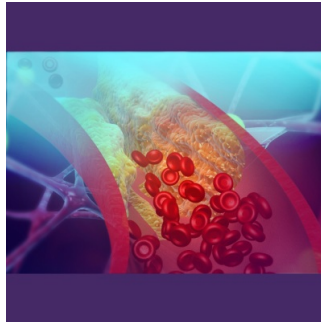

CT-FFR Analysis Lowers Invasive Procedures for Coronary Artery Disease Diagnosis



[In a recent study](#) conducted at Massachusetts General Hospital and published in *Radiology: Cardiothoracic Imaging*, researchers investigated the impact of CT fractional flow reserve (CT-FFR) analysis on patients with significant coronary artery stenosis. The study, conducted between August 2020 and August 2021, focused on patients who underwent coronary CT angiography (CTA) without heart rate control, aiming to assess the efficacy of CT-FFR in guiding clinical decisions and reducing the need for invasive procedures.

Challenges in CAD Diagnosis and the Emergence of CT-FFR

Coronary artery disease (CAD) poses a significant health risk worldwide, often necessitating invasive procedures like invasive coronary angiography (ICA) and percutaneous coronary intervention (PCI) for diagnosis and treatment. However, non-invasive imaging techniques such as coronary CTA have emerged as valuable tools in diagnosing CAD. Despite this, accurately determining the need for invasive procedures based solely on imaging findings remains challenging. Traditional imaging techniques like coronary CTA provide valuable insights into the extent of arterial blockages but may not accurately predict blood flow impairment. This limitation has prompted the development of CT-FFR, a non-invasive method that models coronary blood flow using CTA images, artificial intelligence algorithms, and computational fluid dynamics.

Effectiveness of Selective CT-FFR Utilisation in Reducing Invasive Procedures

The retrospective observational study included 2,985 patients who underwent coronary CTA, with 292 (9.7%) referred for CT-FFR analysis. Among the patients with significant stenosis, those who underwent CT-FFR analysis showed lower rates of ICA (25.5% vs. 74.5%) and subsequent PCI (21.1% vs. 78.9%) compared to those who did not undergo CT-FFR. This selective approach to CT-FFR utilisation proved effective in identifying patients who would benefit most from invasive procedures while sparing others from unnecessary interventions. CT-FFR was particularly beneficial in patients with moderate arterial narrowing, where the need for invasive testing and revascularization procedures may be uncertain. By objectively measuring coronary artery flow, CT-FFR provided physicians with valuable physiological information, guiding decision-making and reducing the ambiguity surrounding treatment options.

CT-FFR's Potential to Transform Clinical Practice

The study's senior author, Dr. Brian B. Ghoshhajra, emphasised the importance of selective CT-FFR utilisation, noting its ability to improve patient outcomes while minimising the need for invasive procedures. Despite potential challenges such as elevated heart rates and obesity, CT-FFR analysis demonstrated success in the majority of patients, underscoring its reliability and clinical utility. Overall, the study findings underscore the potential of CT-FFR to transform clinical practice by reducing the frequency of invasive procedures in patients with significant coronary artery narrowing. By integrating CT-FFR analysis into routine care, clinicians can make more informed treatment decisions, improving patient outcomes and enhancing the efficiency of healthcare delivery.

The study highlights the value of CT-FFR as a non-invasive tool for assessing coronary artery disease and guiding treatment strategies. Moving forward, further research and integration of CT-FFR into clinical practice are warranted to optimise patient care and enhance the management of CAD.

Source: [RSNA Radiology](#)

Image Credit: [iStock](#)

Published on : Wed, 17 Apr 2024

© For personal and private use only. Reproduction must be permitted by the copyright holder. Email to copyright@mindbyte.eu.