

---

## Volume 15 - Issue 1, 2015 - Management Matrix

### Breast MRI: The New Standard in Breast Imaging?



**Dr. Ritse Mann**

\*\*\*\*\*@\*\*\*radboudumc.nl

Breast Radiologist - Radboud  
University Medical Centre

[LinkedIn](#) [Facebook](#)

---

Breast MRI is standard practice in all major breast imaging clinics worldwide. This is due to the unrivalled sensitivity of breast MRI, reported to be between 90 and 95% (Peters et al. 2008; Phi et al. 2014). Moreover, the three-dimensional nature of the examination allows a much better understanding of the spread of eventual disease throughout the breast (see Figure 1). Detailed guidelines on techniques and indications have been published that allow state-of-art practice in virtually any clinic (Mann et al. 2008; Sardanelli et al. 2010). In fact, every new modality on the market is nowadays compared to breast MRI to assess its clinical value. However, breast MRI is also viewed as a very expensive modality that, while presenting beautiful images, does more harm than good. In this article the reasons for these sharp contrasts are discussed, as well as the need for further investigations in the field of breast MRI specifically and breast cancer treatment in general.

#### Preoperative MRI

From the introduction of contrast enhanced breast MRI in the mid-1980s (Kaiser 1985; Heywang et al. 1986), it was clear that a new era in breast imaging had started. It became possible to assess breast cancers in three dimensions, and detect many tumour foci that were completely occult at mammography or ultrasound. In recent years, despite the large improvement in the quality of conventional methods, the additional gain of breast MRI in women with breast cancer remains impressive. Additional tumour localisations, often changing the therapeutic management of the affected breast, are detected in, on average, 20% of patients. Moreover, otherwise undetected second cancers in the other breast are found in up to 5.5% of women (Plana et al. 2012).

Transition of these findings to therapeutic protocols and operating theatres is slow. This has several major reasons: the first is that from pathology studies it has always been clear that not all cancer present in the breast is visible in imaging studies. In fact this has been exploited, as tumour resections are nowadays aimed at removing the palpable or visible tumour and not so much at complete excision of all cancer present in the breast. After surgical debulking, radiotherapy and adjuvant chemo- and hormonal therapies are supposed to treat the remaining cancer cells. Considering the relatively low recurrence rate of between 2 and 8% in 10 years, this apparently works, thus an additional imaging test that shows more cancer in the affected breast may only increase the surgical volume, decrease the cosmetic outcome and thus negatively impact on the overall quality of life of women with breast cancer (Morrow 2004).

However, leaving large amounts of residual cancer within the breast is still detrimental for the overall outcome, and consequently margin assessment is performed on all surgical resections. In case of tumour infiltration of the margins re-excisions are performed, thus exposing women to repeat operations that could have been prevented by adequate use of the information in a decently performed breast MRI. This brings us, however, to the second reason that adaptation of clinical protocols and surgical procedures is slow: translating the information from MRI to the operating room (OR) is difficult. Women are positioned in a completely different position in the two situations, and since the breast is pliable the relative position of the cancer to major landmarks such as the nipple and the sternum shifts substantially. This likely explains also why the first large study on the effect of breast MRI on re-excision rates failed to show any benefit from MRI (Turnbull et al. 2010), while some single centre investigations document a strong impact (Mann et al. 2010; Sung et al. 2014). The three-dimensional appreciation of this shift demands extensive practice. Nevertheless, experienced surgeons will nowadays, based on the MRI findings, attempt lumpectomies in patients, who would definitively have undergone mastectomies without this additional information, and will reduce the volume of tissue removed in many others.

While it is evident that tumours that appear much larger on MRI than on conventional imaging techniques must be excised in toto, it is unclear how to deal with incidentally discovered additional tumour foci away from the primary tumour. In the early days of breast MRI such findings would invariably lead to mastectomy and hence a more extensive operation than was actually needed. Only now is it admitted that treating those foci in some women might only negatively impact the outcome, and it might be wiser to follow such findings. Unfortunately, there are no clear cut offs to determine which lesions should, and which lesions should not, be surgically treated. This is a clear field for further multidisciplinary investigations. It also demands a different approach to informing women with breast cancer. Too often the fact that surgery is commonly not

curative in itself is ignored, and women are being told that adjuvant therapies are mainly a safeguard and not part of the primary therapy. Understanding the real meaning of breast-conserving therapy is essential for the adequate use of breast MRI in the preoperative setting, and guidelines for women's information are currently in press.

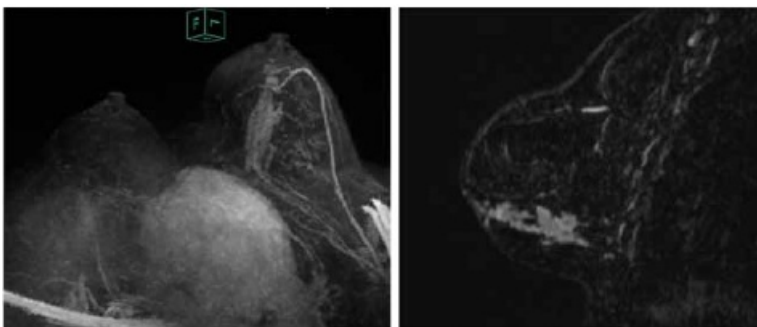
Further clinical indications for breast MRI are less disputed. Breast MRI is clearly the most effective method for the monitoring of patients treated with neoadjuvant chemotherapy, and is undoubtedly valuable in women with metastasis from an unknown primary cancer. Its high negative predictive value (NPV) can also be exploited in problem cases where biopsy is not possible (Mann et al. 2008).

## Screening

The high sensitivity of breast MRI has sparked a strong interest in the technique as a screening modality. At first, some reservations were in place, because of the presumably somewhat lower sensitivity of MRI for ductal carcinoma in situ (DCIS), the non-invasive precursor of breast cancer. This was due to the fact that breast MRI only detects approximately 85% of calcified DCIS lesions discovered by mammography (Bazzochi et al. 2006). However, it is now evident that DCIS does only calcify in approximately half of the cases. In fact, if all lesions are considered and not only those that calcify, the sensitivity of breast MRI for DCIS is much higher than that of mammography (Kuhl et al. 2007). From the start of this century, and now backed by these findings, multiple studies have evaluated the added cancer detection rate of breast MRI in women at intermediate and high risk. Each of these studies showed that breast MRI virtually doubles breast cancer detection when compared to a screening regimen based on mammography only. In an early meta-analysis a sensitivity of 77% was documented for MRI, compared to 39% for mammography (Warner et al. 2008). While the MRI sensitivity is clearly much higher than that of mammography, this figure still appears poor compared to the results in staging MRI. This is explained by the fact that screening breast MRI is different from MRI as a staging modality. Lesions are often smaller (and thus still occult on mammography), and have fewer classic features of malignancy. Consequently, a learning process had to be observed. This likely explains why the reported sensitivities of newer studies that were not included in the initial meta-analyses are, at respectively 93% (Kuhl et al. 2010) and 91% (Sardanelli et al. 2011), much higher than in earlier studies. It is also backed by the fact that recent reports from groups that performed early screening studies now also report an equally high sensitivity (Obdeijn et al. 2014).

A common objection to breast MRI as a screening tool is that the specificity is lower than that of mammography. Breast MRI does detect many more lesions, both benign and malignant, and separation based upon imaging characteristics is not always possible. However, care must be taken not to confuse the specificity of mammography screening with that of MRI in clinical cases. In screening most cases are normal. Consequently, the specificity of any screening test is very high. For mammography the specificity is reported to be in the order of 99%; this only drops slightly to approximately 96% with MRI screening (Morrow et al. 2011). It is likely more important to evaluate the positive predictive value (PPV) of screening induced biopsies, as unneeded biopsies for benign abnormalities are among the most unwanted side effects of screening. This figure ranges between 25 and 48%, and is in general terms virtually equal to the PPV of mammography induced biopsies (Saslow et al. 2007; Warner et al. 2008; Morrow et al. 2011), and much higher than the 10% or less that is normally reported for ultrasound screening (Berg et al. 2012; Brem et al. 2014). Since radiologists will always include a range of error in their indication for breast biopsies (1 in 3 biopsies positive for cancer is quite acceptable for most radiologists), it is unlikely that the PPV for MRI-detected lesions will increase much. It is therefore essential to inform women screened with MRI that the likelihood of biopsy due to MR screening increases as more cancers are detected, but in an equal fraction also more benign lesions. In the end, women should evaluate whether or not they find for themselves this increased risk of a negative breast biopsy worth the chance of earlier cancer detection.

The success of MRI screening in the high-risk population has induced further screening studies in women at average risk in whom mammographic breast screening fails. Especially in women with dense breasts the sensitivity of mammography is reduced. Based upon mammographic literature, this sensitivity is approximately 50 to 60% at a detection rate of around 4 cancers per 1000 screens. However, supplemental MRI screening subsequently detects a staggering 14.7 cancers per 1000 screens that were not observed on mammography (Berg et al. 2012), hence reducing the actual mammographic sensitivity to less than 25%. Naturally, this is a prevalence screen and it is unlikely (and unwanted) that in subsequent rounds equally high detection rates will be observed, but it clearly shows the potential of breast MRI to detect breast cancers earlier and hence improve the overall prognosis. Moreover the exceptionally high NPV of breast MRI in this setting allows honest reassurance of anxious women after a negative scan.



**Figure 1.** Large segmental DCIS lesion in the lower outer quadrant of the left breast. In the left frame a slightly rotated maximum intensity projection is depicted that shows the total lesion clearly. The right frame shows a sagittal reconstructed subtraction image documenting the extent of this lesion from the nipple, almost to the thoracic wall.

## Cost Issues

That breast MRI is still not widely adopted as a screening modality is largely a cost issue. The costs of a single MRI scan are at least 4 to 5 times higher than that of a mammogram and, since the actual gain in quality-adjusted life years based upon the earlier detection of breast cancers with MRI is not known, estimates on cost-effectiveness vary widely (Taneja 2009). Cost-effectiveness is questioned for all women, except those at the highest risk, mainly women with BRCA 1 and BRCA 2 mutations. The task for the radiological scientific community is thus to reduce the costs to

an acceptable level for mass screening. One approach is to largely reduce the scan protocol to the most basic sequences only. The scan length is then reduced to one-fifth of the full protocol, while the sensitivity is approximately 90% of the full scan and the NPV is hardly affected (Kuhl et al. 2014). This reduces the costs to approximately one third of the full scan, since patient positioning remains the same and reporting costs are only slightly reduced. To preserve specificity in such a shortened scan protocol ultrafast dynamic sequences can be employed that provide information to increase specificity that actually outperform the conventional dynamic approach, while reducing the scan time even further (Mann et al. 2014). A further option would be to abandon mammography in women screened with MRI, since the added detection of mammography after a negative MRI is very low (Kuhl et al. 2010; Obdeijn et al. 2014), while women are still exposed to discomfort and ionising radiation. These new approaches have not yet been validated in prospective screening trials, and are hence not yet applied in clinical practice. Designing large multi-institutional and preferably multinational screening studies is thus of utmost importance to exploit breast MRI to its full potential.

## **Conclusion**

Breast MRI is in fact the new standard in breast imaging. However, it is unsure how to use this new standard for optimisation of treatment protocols that are still based upon findings from conventional imaging studies. Furthermore, bringing the costs of breast MRI under control is essential for its future as a screening tool. Multicentre and multidisciplinary investigations are essential to alleviate these issues in the near future.

## **Key Points**

- Breast MRI is the current gold standard in breast imaging in terms of cancer detection.
- Breast MRI largely changes the oncologic profile of breast cancer and has a major influence on treatment.
- Breast MRI is a vital part of current day-to-day breast imaging and has great potential for screening.

Published on : Sat, 28 Feb 2015