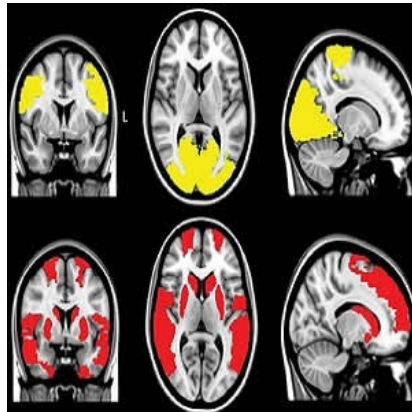




Brain disconnections may cause Parkinson's hallucinations



With the use of functional MRI (fMRI), researchers have been able to study the mechanism underlying visual hallucinations in Parkinson's disease. Their main finding: these visual hallucinations may be triggered by disconnections of brain areas involved in attention and visual processing.

The disconnected brain areas seen on fMRI may be valuable in predicting the development of visual hallucinations in patients with Parkinson's disease, according to the study published in the journal *Radiology*.

The researchers used resting-state fMRI to examine the connectivity between brain areas. The connectivity was measured in 15 patients with visual hallucinations, 40 patients without visual hallucinations, and 15 healthy controls by calculating the level of synchronisation between activation patterns of different brain areas.

The results showed that in all the patients with Parkinson's disease, multiple brain areas communicated less with the rest of the brain as compared to the control group. Notably, in patients experiencing visual hallucinations, several additional brain areas showed this decreased connectivity with the rest of the brain — especially in areas that are important in maintaining attention and processing of visual information.

"We found that the areas in the brain involved in attention and visual processing were less connected to the rest of the brain," said study author Menno M. Schoonheim, PhD, from the Department of Anatomy and Neurosciences at VU University Medical Center (VUMC) in Amsterdam, the Netherlands. "This suggests that disconnection of these brain areas may contribute to the generation of visual hallucinations in patients with Parkinson's disease."

While there are no direct therapeutic implications for patient care based on the research, the authors note that future studies could indicate whether techniques that could stimulate the areas with decreased connectivity could be helpful to treat visual hallucinations in people with Parkinson's disease.

Source: [Radiological Society of North America](#)

Image Credit: RSNA

Published on : Wed, 4 Oct 2017