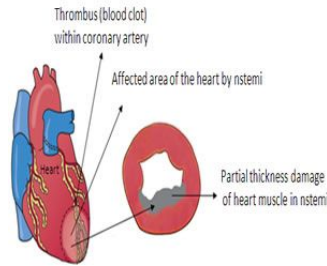


Atrial Fibrillation Increases Risk of NSTEMI



New research suggests that atrial fibrillation or irregular heartbeat is associated with only one type of heart attack. The study was led by Elayed Z. Soliman, MD, Director of the Epidemiological Cardiology Research Center at Wake Forest Baptist Medical Center and is published in the American Heart Association Journal *Circulation*.

Atrial fibrillation is the most prevalent heart rhythm disorder and affects nearly 6 million Americans. It is also a risk factor for stroke. Soliman led a study in 2013 that showed that atrial fibrillation increased the risk of heart attack by 70 percent. The risk was found to be even higher in women and African-Americans.

The results have now been further refined. Soliman and his team reviewed the histories of 14,462 people who were part of the Atherosclerosis Risk in Communities (ARIC) study, a National Heart, Lung and Blood Institute-funded research project. The review confirms that atrial fibrillation increases the risk of heart attack by 63 percent with a higher rate in women. It also determined that the association was limited to the type of attack known as NSTEMI (non-ST segment elevation myocardial infarction).

NSTEMI occurs when a blood clot partly clogs a coronary artery and only a portion of the heart muscle supplied by the artery is damaged. It is the most common type of heart attack and nearly two-thirds of the 735,000 heart attacks reported in the US are NSTEMI.

The findings clearly show that atrial fibrillation is associated only with NSTEMI heart attacks and that factors contributing to partial blockage of the coronary arteries or increased oxygen demand are more likely to explain this association.

"These results have important implications for management of the risk of heart attack in people with atrial fibrillation," Soliman said. "For example, blood thinners that are commonly prescribed to people with a-fib to prevent stroke may not be as effective in preventing heart attacks in this population."

Source: Wake Forest Baptist Medical Center

Image Credit: NSTEMI.org

Published on : Sun, 3 May 2015