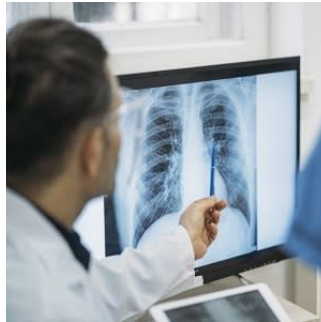

AI Accurately Identifies Normal and Abnormal Chest X-Rays



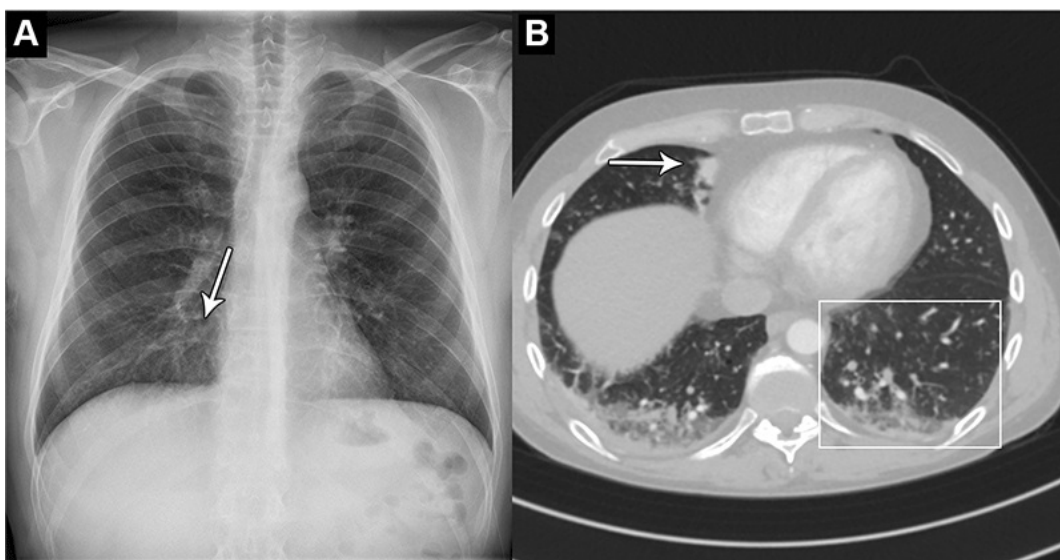
An AI tool can accurately identify normal and abnormal chest X-rays in a clinical setting, according to a study published in [Radiology](#). The tool may greatly alleviate the heavy workload experienced by radiologists globally.

“There is an exponentially growing demand for medical imaging, especially cross-sectional such as CT and MRI,” said study co-author Louis Lind Plesner, MD, from the Department of Radiology at the Herlev and Gentofte Hospital in Copenhagen, Denmark. “Meanwhile, there is a global shortage of trained radiologists. Artificial intelligence has shown great promise but should always be thoroughly tested before any implementation.”

For this retrospective, multi-center study, Dr. Plesner and colleagues wanted to determine the reliability of using an AI tool to identify normal and abnormal chest X-rays.

They used a commercially available AI tool to analyze the chest X-rays of 1,529 patients from four hospitals in the capital region of Denmark. Chest X-rays were included from emergency department patients, in-hospital patients and outpatients. The X-rays were classified by the AI tool as either “high-confidence normal” or “not high-confidence normal” as in normal and abnormal, respectively.

Two board-certified thoracic radiologists were used as the reference standard. A third radiologist was used in cases of disagreements, and all three physicians were blinded to the AI results.



Images in a 44-year-old man who presented with chest pain and dyspnea. (A) Chest X-ray shows very subtle nodular opacities, primarily in lower lobes, representative of pneumonia and a discrete silhouette sign of the right cardiac border (arrow). The AI system interpreted this chest X-ray as normal. It was also interpreted as normal in the

clinical radiology report. (B) CT scan shows the lower lobe airspace opacities with vague tree-in-bud morphology (box) and an area of consolidation (arrow). Pulmonary angiography was performed 5 hours after X-ray. This was the sole false-negative "critical" finding by the AI tool. <https://doi.org/10.1148/radiol.222268> © RSNA 2023

Tool Identifies Abnormal Chest X-Rays with 99.1% Sensitivity

Of the 429 chest X-rays that were classified as normal, 120, or 28%, were also classified by the AI tool as normal. These X-rays, or 7.8 % of all the X-rays, could be potentially safely automated by an AI tool. The AI tool identified abnormal chest X-rays with 99.1% sensitivity.

"The most surprising finding was just how sensitive this AI tool was for all kinds of chest disease," Dr. Plesner said. "In fact, we could not find a single chest X-ray in our database where the algorithm made a major mistake. Furthermore, the AI tool had a sensitivity overall better than the clinical board-certified radiologists."

According to the researchers, further studies could be directed toward larger prospective implementation of the AI tool where the autonomously reported chest X-rays are still reviewed by radiologists.

The AI tool performed especially well at identifying normal X-rays of the outpatient group at a rate of 11.6%. This suggests that the AI model would perform especially well in outpatient settings with a high prevalence of normal chest X-rays.

"Chest X-rays are one of the most common imaging examinations performed worldwide," Dr. Plesner said. "Even a small percentage of automatization can lead to saved time for radiologists, which they can prioritize on more complex matters."

Source: <https://www.rsna.org/news/2023/march/ai-identifies-normal-abnormal-xrays> target="_blank">RSNA

Image Source: <https://www.istockphoto.com/> target="_blank"> iStock

Published on : Thu, 16 Mar 2023