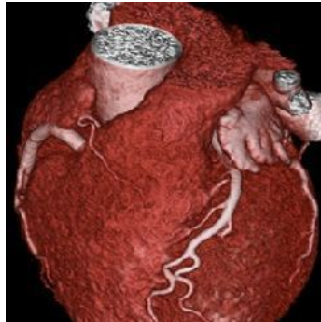

Trial to Compare CT, Cardiac Catheterisation



A new European randomised study ([DISCHARGE](#)) aims to determine whether computed tomography (CT) can replace cardiac catheterisation in evaluating patients with suspected coronary artery disease (CAD). Marc Dewey, Heisenberg Professor of Radiology at the [Charité University Hospital](#) in Berlin, coordinates the study, taking place at 25 clinical sites in 16 European countries.

Cardiac catheterisation is the gold standard for diagnosing CAD, the main cause of death worldwide. More than 3.5 million invasive coronary angiographies (ICAs) are performed in the European Union each year. Nearly 60 percent of these minimal invasive examinations do not result in further treatment, since the patients do not have obstructive epicardial coronary artery stenosis. For these patients non-invasive cardiac CT could be advantageous.

ICA allows minimally invasive treatment of coronary stenosis during the examination. However, the invasive technique includes a risk of serious side effects for about one percent of the patients. "For patients with suspected CAD with a low-to-moderate risk (10-60 percent), non-invasive CT might provide a better risk/benefit ratio in favour of the patient," says Prof. Dewey. "Early detection and improved characterisation of coronary plaques in the entire coronary artery tree is also very well possible with CT. Certain unique high-risk plaque features have been also shown to predict subsequent events and outcomes if assessed by CT."

DISCHARGE currently examines for which patients with suspected CAD based on stable chest pain, CT or invasive coronary angiography is preferable. More than 3,500 patients will be recruited within the next two years for the study from now on, with a maximum follow-up of four years. The major goal of the trial is to examine whether CT helps to reduce myocardial infarction, stroke, and cardiovascular death.

CT imaging also allows the examination of tissues surrounding the heart: lungs, oesophagus and spine may be checked for instance. This may result in a diagnosis explaining chest pain and suggesting appropriate treatment, which could be overlooked by ICA.

"ICA is the best way to treat known CAD. But in a situation where ruling out diagnosis of CAD is likely, CT, with its tremendously improved image quality, might prove to be the best method available," Prof. Dewey points out.

Currently, CT has little role in diagnosis of CAD and is not reimbursed for this purpose in most European countries yet. There are other imaging modalities to rule out CAD besides CT such as stress MRI, PET/CT, SPECT and stress echocardiography. These perfusion-imaging tests enable to search for stress-induced ischaemic myocardial areas and play an important role in clinical decision-making in the DISCHARGE trial in case of anatomic coronary stenosis found by CT with unclear functional relevance.

"Ultimately, DISCHARGE aims to provide the basis for new guidelines in cardiac imaging," says Prof. Dewey. "Therefore, we are closely collaborating not only with clinical sites, but also with non-clinical partners to optimise the impact of the study for the benefit of the different European health systems."

Sources: [DISCHARGE Trial](#); [Charité Berlin – Department of Radiology](#)

Image credit: Prof. Dr. Marc Dewey, Charité Berlin

Published on : Tue, 20 Oct 2015