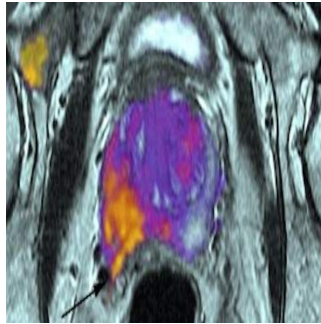


---

## RSI-MRI Detects Spread of Cancer Beyond Prostate



---

A pilot clinical study involving nine prostate cancer patients has compared standard MRI with a new clinical imaging technique that has the ability to identify less severe forms of the disease, potentially saving patients unnecessary treatment. The new technique generates more precise images so that surgeons are better able to determine the extent and exact location of a tumour, thereby sparing healthy tissue and improving treatment plans. The findings appear in *Prostate Cancer and Prostatic Disease*.

A team of researchers from the University of California, San Diego (UCSD) and the University of California, Los Angeles (UCLA) developed the technique of restriction spectrum imaging MRI, or RSI-MRI, which corrects for magnetic field distortion to provide a more precise picture of tumour position compared with the currently used diffusion MRI. Diffusion MRI improves on standard contrast MRI, the researchers explain, but one drawback to the technique is that magnetic field artefacts can distort the location of the tumour.

"RSI-MRI corrects for this distortion, improving the accuracy of MRI to localise tumours," said Nate White, PhD, Assistant Professor of Radiology at UCSD.

The research team found that RSI-MRI correctly identified extraprostatic extension (EPE) in all but one of the nine patients participating in the study. Meanwhile, standard MRI found EPE in only two of the nine patients. The presences of EPE means that a tumour has spread beyond the prostate into surrounding tissue, an indicator of advanced disease that necessitates more aggressive treatments.

"Current imaging of prostate cancer is done with contrast-enhanced MRI. Unfortunately, some tumours fail to show a marked difference from surrounding healthy tissue due to lack of uptake of the contrast agent," said Anders Dale, PhD, Professor of Radiology at UCSD.

The success of RSI-MRI is encouraging since it could help to determine disease severity for the planning of appropriate treatment schedules. "And, in cases where surgery is warranted, the accurate RSI-MRI image will also guide a more discriminating surgery to completely remove the tumour while sparing surrounding healthy tissues; this is an important consideration for allowing patients to maintain sexual function and urinary control following surgery," said David S. Karow, MD, PhD, corresponding author and Assistant Professor of Radiology at UCSD.

Further research in a larger patient population will improve upon these findings, the researchers say.

Prostate cancer is the most commonly diagnosed form of cancer in men, after skin cancer. The American Cancer Society predicts 220,800 new cases of prostate cancer and 27,450 prostate cancer deaths in 2015.

Funding for the project was provided in part by a National Institute of Biomedical Imaging and Bioengineering (NIBIB) award of the National Institutes of Health, the Department of Defense's Prostate Cancer Research Program, the American Cancer Society and the UCSD Clinician Scientist Program.

Source: National Institute of Biomedical Imaging and Bioengineering

Image Credit: David Karow, UCSD

