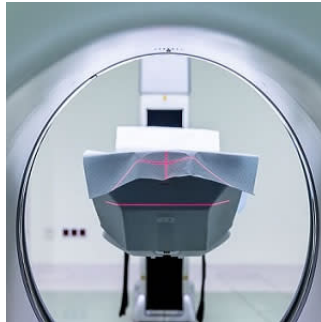


---

## MRI detects abdominal pregnancy better than ultrasonography



---

Abdominal pregnancy is a rare type of ectopic pregnancy that is potentially life-threatening for both the mother and foetus. This dangerous medical condition can be easily missed in routine obstetric practice, even in routine antenatal ultrasonography. A new study in China highlights the importance of magnetic resonance imaging (MRI) in abdominal pregnancies, which figures the exact anatomical relationships of the foetus, the placenta, and maternal intra-abdominal organs, thus contributing to surgical intervention.

Many abdominal pregnancies progress into advanced gestational age, thus diagnosis of foetal severe congenital abnormalities is important. An MRI can help to exclude these abnormalities, according to study authors, Mei-xiang Deng, MM and Yu Zou, MD, both with the Department of Radiology, Women's Hospital, School of Medicine, Zhejiang University, Hangzhou, Zhejiang, China.

Their study focused on one case of abdominal pregnancy which continued into the third trimester. A 24-year-old woman at 33 weeks' gestation presented to local hospital complaining of vaginal bleeding for two months and lower abdominal pain for two days. The authors said the woman was transferred to their centre for suspected abdominal pregnancy, which was confirmed at the centre on ultrasonography and further evaluated in detail on MRI.

The woman was managed surgically, the unviable foetus was removed, and the placenta was left in situ. Then, the woman was managed with fluids, blood transfusion, antibiotics, and systemic methotrexate after surgery. At 42 days postoperatively, according to the authors, the affected woman was discharged in a good condition.

"By using MRI, we can accurately diagnose an abdominal pregnancy. MRI provides more details than ultrasonography, and explains the possible mechanism of abdominal pregnancy. We advocate using MRI to help surgical planning and improve outcome in cases of abdominal pregnancy," the authors wrote.

Deng and Zou also highlight important elements that radiologists must focus on when evaluating an MRI for cases of suspected abdominal pregnancy:

- 1) Foetus: determination of intra-abdominal extrauterine foetal presence; lie, position, and relation to the uterus and maternal intra-abdominal organs; viability; congenital abnormalities; signs of foetal demise/ maceration/hydrops.
- 2) Placenta: site and extent of implantation; most possible placental blood supply; bleeding of placental bed; placental infarction.
- 3) Amniotic sac: oligohydramnios; signs of rupture of membrane and leakage of amniotic fluid.
- 4) Uterus: integrity of cervix, uterine wall, and endometrial cavity; signs of uterine rupture and possible exit of the embryo/foetus.
- 5) Nature of the intra-abdominal fluid and amniotic fluid: haemorrhagic or clear.
- 6) Any maternal pathology detected by chance, such as uterine and ovarian neoplasms.

In particular, the identification of the site and extent of placenta on MRI can affect the decision whether to remove or leave the placenta in situ, and direct the operating obstetrician to open the abdomen via correct incision, thereby avoiding a catastrophic haemorrhage once the placental bed is incised, the authors explain.

Source: [Medicine](#)

Image Credit: Pixabay

Published on : Tue, 23 Jan 2018