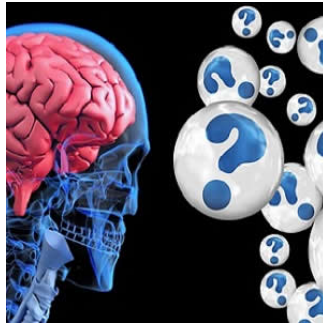


## AI-based neuroimaging approach helps predict Alzheimer's disease



Machine learning techniques such as support vector machine (SVM) have been applied recently in order to accurately classify individuals with neuropsychiatric disorders such as Alzheimer's disease (AD) based on neuroimaging data. However, the multivariate nature of the SVM approach often precludes the identification of the brain regions that contribute most to classification accuracy. New research shows a multiple kernel learning approach highlights the high discriminative weight of a subset of brain regions of known relevance to AD, which helps in classifying patients with mild AD versus age- and gender-matched healthy controls.

Multiple kernel learning (MKL) is a sparse machine learning method that allows the identification of the most relevant sources for the classification. By parcelating the brain into regions of interest (ROI) it is possible to use each ROI as a source to MKL (ROI-MKL).

In this study, researchers applied MKL to multimodal neuroimaging data in order to: 1) compare the diagnostic performance of ROI-MKL and whole-brain SVM in discriminating patients with AD from demographically matched healthy controls and 2) identify the most relevant brain regions to the classification. Researchers used two atlases (AAL and Brodmann's) to parcelate the brain into ROIs and applied ROI-MKL to structural (T1) MRI, 18F-FDG-PET and regional cerebral blood flow SPECT (rCBF-SPECT) data acquired from the same subjects (20 patients with early AD and 18 controls).

In ROI-MKL, each ROI received a weight (ROI-weight) that indicated the region's relevance to the classification. For each ROI, researchers also calculated whether there was a predominance of voxels indicating decreased or increased regional activity (for 18F-FDG-PET and rCBF-SPECT) or volume (for T1-MRI) in AD patients.

Compared to whole-brain SVM, the ROI-MKL approach resulted in better accuracies (with either atlas) for classification using 18F-FDG-PET (92.5% accuracy for ROI-MKL versus 84% for whole-brain), but not when using rCBF-SPECT or T1-MRI, the researchers noted. Although several cortical and subcortical regions contributed to discrimination, high ROI-weights and predominance of hypometabolism and atrophy were identified especially in medial parietal and temporo-limbic cortical regions. Also, the weight of discrimination due to a pattern of increased voxel-weight values in AD individuals was surprisingly high (ranging from approximately 20% to 40% depending on the imaging modality), located mainly in primary sensorimotor and visual cortices and subcortical nuclei.

"Our PET findings reinforce the view that the macroscopic brain metabolic patterns that most critically typify the probable diagnosis of AD on an individual basis remain relatively localised even when clear symptoms of dementia are already present," the authors write. "By highlighting the same brain regions emphasised in previous studies investigating the clinical utility of 18F-FDG-PET data to allow diagnostic predictions in individual elderly subjects, our findings strengthen the potential usefulness of ML-based approaches in clinical practice."

While similar diagnostic accuracy indices were obtained with the MKL-ROI and whole-brain methods for T1-MRI and rCBF SPECT data, the authors found an increment in accuracy for the PET data when applying the MKL-ROI-based method (with both atlases). This finding underscores the relevance of functional activity decrements in circumscribed posterior cortical regions as a critical imaging feature for the early diagnosis of AD, the authors explain.

Source: [NeuroImage: Clinical](#)

Image Credit: Pixabay

Published on : Fri, 22 Dec 2017