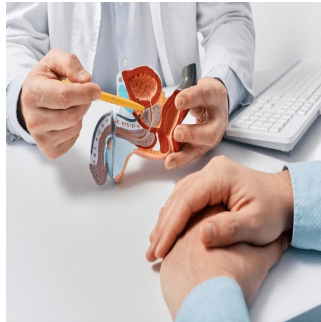

Prostate Cancer Surveillance can be Enhanced with Advanced MRI Techniques



Active surveillance (AS) is endorsed by the European Association of Urology (EAU) for low to favourable intermediate-risk prostate cancer (PCa) patients. It aims to delay or avoid radical treatments while maintaining oncological outcomes. AS's safety is supported by trials like ProtecT and PIVOT, despite potential understaging and undergrading. AS involves regular monitoring of PSA, MRI, and repeat biopsies, with eligibility criteria based on Gleason score, PSA levels, and clinical stage. MRI has become crucial for AS eligibility and ongoing monitoring, improving risk classification and reducing under-sampling. Negative MRI indicates lower-grade pathology suitable for AS, while PI-RADS score predicts higher-grade disease. MRI's relatively low positive predictive value (PPV) for disease progression suggests caution in using it alone to trigger biopsies or treatment, emphasizing its role alongside clinical factors like PSA dynamics. [A recent review published in *European Radiology*](#) delves into MRI's current role in AS, emphasising the need for contrast-enhanced sequences.

Biparametric and Multiparametric MRI Protocols for Prostate Cancer Diagnosis

The PI-RADS v2.1 guidelines recommend a full multiparametric MRI (mpMRI) protocol for suspected localized or locally advanced prostate cancer, including T2-weighted, diffusion-weighted imaging (DWI), and dynamic contrast-enhanced (DCE) sequences. However, the use of Gadolinium-based contrast agents in MRI poses risks such as allergic reactions and potential long-term deposition in certain brain regions. Biparametric MRI (bpMRI), comprising T2- and DWI sequences without contrast, offers advantages like cost savings and fewer side effects. In initial diagnosis, bpMRI may be preferred if high-quality imaging and expert interpretation are available. Studies show comparable performance between bpMRI and mpMRI, although mpMRI may have slightly higher sensitivity. Prospective studies are underway to further investigate this issue.

Standardising MRI Monitoring in Active Surveillance for Prostate Cancer

During the active surveillance (AS) monitoring phase, EAU guidelines suggest using MRI for men with rising PSA, but the frequency and intensity of follow-up aren't standardised. MRI may occur routinely or based on PSA kinetics or clinical signs. Some centres adopt risk-based, tailored approaches for personalised AS. PRECISE recommendations offer a standardised tool to assess radiological progression on MRI during AS, categorising stability or change into five scores. Signs of progression include increased conspicuity, higher PI-RADS score, new lesions, enlarged lesions, or worsening stage. While the role of DCE isn't explicitly discussed, it relates to lesion conspicuity. Challenges arise in patients with prostatitis due to diffuse changes, especially on T2W and DCE. Robust data to establish thresholds for significant change are lacking, though a recent study suggests a 20% increase in T2W size or a 10% decrease in ADC values. Despite PRECISE limitations, a systematic review suggests improved performance over institute-specific systems due to a more objective categorization of progression.

Optimising MRI Protocols for effectiveness and impact on patient outcomes

The PRECISE guidelines, developed through multidisciplinary consensus, emphasise that MRI protocols for active surveillance (AS) should align with the PI-RADS criteria. However, they do not explicitly state whether contrast administration is necessary. The growing demand for AS scans has led to the exploration of shortened protocols, which offer advantages such as cost savings and reduced risk associated with contrast agents.

During AS follow-up, the primary goal of MRI is to detect "radiologically significant" progression, which is typically defined as a PRECISE score of 4–5. This monitoring is complemented by regular PSA checks and protocol-driven repeat biopsies. While contrast-enhanced MRI may not be essential for all AS patients, it is recommended for those at higher risk of disease progression, such as those with fast PSA doubling times or changing clinical or pathologic status.

Although limited studies are comparing contrast-enhanced MRI to a biparametric approach in AS, meta-analyses suggest that biparametric MRI performs similarly to multiparametric MRI in this context. The higher specificity of biparametric MRI may be advantageous for AS patients as it reduces the likelihood of unnecessary biopsies. However, there are considerations to be made regarding the use of biparametric MRI. For

example, dynamic contrast enhancement (DCE) sequences, which are omitted in biparametric MRI, provide valuable information but also pose challenges due to their non-specificity. False-positive results can occur due to factors such as prostatitis or benign prostatic hyperplasia (BPH), necessitating careful interpretation alongside T2-weighted and diffusion-weighted imaging sequences.

Additionally, new lesions identified on follow-up scans may not always be clinically significant. A risk-tailored approach using biparametric MRI may help reduce unnecessary biopsies for patients with low PSA doubling times. Despite its advantages, biparametric MRI may also have limitations. For example, it may increase the number of indeterminate lesions and could affect inter-reader agreement for PRECISE scoring, particularly as scoring agreements have primarily been assessed using multiparametric MRI.

Overall, while biparametric MRI offers potential benefits for AS patients, further research is needed to fully understand its effectiveness and impact on patient outcomes in this context.

Integrating MRI and AI for Improved Active Surveillance Management

Artificial intelligence (AI) techniques, particularly deep learning-based reconstruction algorithms, are increasingly utilized in clinical settings to reduce image noise, thereby potentially improving image quality and reducing scan time. This technology holds promise for enhancing the quality of biparametric MRI (bpMRI) scans, particularly in the context of active surveillance (AS) for prostate cancer. While current guidelines like Prostate Imaging Quality (PI-QUAL) and PRECISE do not specifically address the assessment of AS follow-up MRI quality, upcoming versions are expected to incorporate such considerations. Recent studies have focused on developing AI-assisted solutions to predict and assess the risk of tumour progression in AS, primarily using bpMRI approaches. These studies have demonstrated comparable performance of AI models to expert-derived assessments, indicating the potential for AI to assist less experienced readers. Additionally, combining longitudinal bpMRI data with serial PSA density has shown improved predictive performance compared to using serial MRI results alone. AI tools also have the potential to provide automated measurements of tumour characteristics, such as diameter or volume, which could contribute to more objective image interpretation in the future.

Balancing Safety and Efficacy with Biparametric MRI

MRI has become a standard tool for monitoring disease in patients undergoing active surveillance (AS) for prostate cancer. To cope with increased demand for imaging services, shortened MRI protocols, particularly biparametric MRI (bpMRI), are gaining traction due to their ability to aid patient throughput while avoiding potential side effects associated with contrast agents. Data from studies involving biopsy-naïve patients suggest comparable performance between bpMRI and multiparametric MRI (mpMRI). However, prospective studies such as the PRIME and PACIFIC trials are awaited to confirm these findings. In the context of AS follow-up, bpMRI is viewed as a lower-risk approach, focusing on assessing disease progression rather than lesion detection. The ongoing clinical assessment serves as an additional safety net. The improved specificity of bpMRI could potentially enhance the positive predictive value (PPV) of MRI and reduce the need for repeat biopsies, considering the low disease-specific mortality associated with AS. However, contrast-enhanced MRI offers advantages such as better image quality, increased staging accuracy, and improved lesion detection.

Retrospective single-centre studies and data from biopsy-naïve patient populations suggest that bpMRI is a reasonable approach for AS follow-up, provided quality control measures are met. The technique offers several benefits, and the emergence of AI solutions may further enhance its utility. Nevertheless, further prospective data are needed to establish the safety and efficacy of bpMRI in AS follow-up definitively.

Source: [European Radiology](#)

Image Credit: [iStock](#)

Published on : Thu, 2 May 2024